ELSEVIER

Seminars in
ULTRASOUND
CT and MRI

Imaging of the Paranasal Sinuses and Nasal Cavity: Normal Anatomy and Clinically Relevant Anatomical Variants

Timothy J. Beale, FRCR, FRCS,* Gitta Madani, FRCR,† and Simon J. Morley, FRCR*

Anatomy is the foundation on which the understanding of pathological processes in radiology is based. This article describes the anatomy of the sinonasal region and the clinically relevant anatomical variants, highlighting the need for multiplanar reconstructions as a routine part of the examination when reviewing this region.
Semin Ultrasound CT MRI 30:2-16

Computed tomography (CT) is the modality of choice when assessing inflammatory sinus disease and is routinely performed prior to functional endoscopic sinus surgery, the aim of which is to restore the normal mucociliary drainage pathways.

It is important for the radiologist to understand the anatomy of the drainage pathways and the frequent anatomical variants in this region in order to guide the surgeon.

These variants may impair the functional drainage pathways, increase the risk of endoscopic surgery, and make access to sites of disease extremely difficult.

The aim of this review is to highlight the clinically relevant sinonasal anatomy and variants.

Anatomy

CT sinus studies are acquired axially with the patient lying supine avoiding dental artifact. From this data multiplanar reformatted images in both the coronal and the sagittal planes are routinely obtained and are vital when assessing the occasionally complex and variable sinonasal anatomy. In addition soft-tissue reconstruction of the same raw data is helpful in assessing the orbits, frontal lobes, and nasopharynx, which are also covered in the same scan volume.

The anterior ostiomeatal unit (OMU) is the key to the drainage of the anterior sinuses (frontal, anterior ethmoidal, and maxillary) and the spheno-ethmoidal recess draining the posterior sinuses (posterior ethmoidal and sphenoid) is also called the posterior OMU.

The anterior OMU comprises the maxillary sinus ostia and ethmoid infundibulum, hiatus semilunaris, middle meatus, anterior ethmoidal air cells, and frontal recess (Fig. 1).

Frontal Sinus and Frontal Recess

The frontal sinuses are extensions of the anterior ethmoidal air cells and are usually not fully developed until after puberty. In one review of 800 CT studies there was no extension

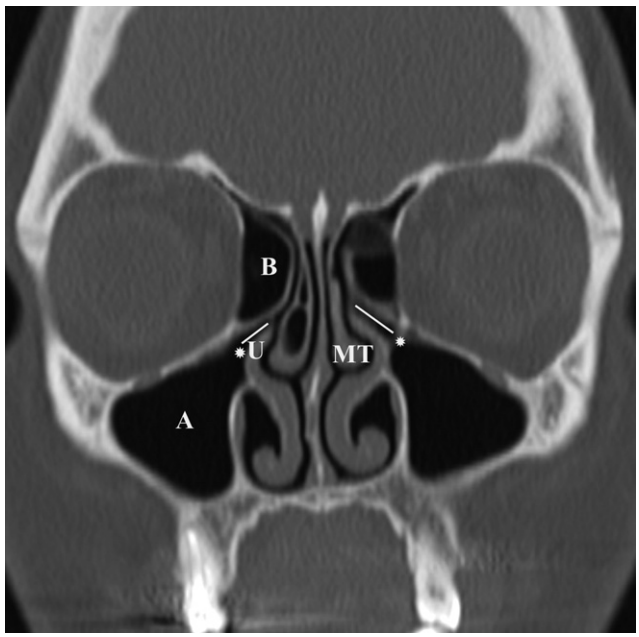

Figure 1 Coronal CT highlighting the anterior OMU anatomy: A = antrum; B = ethmoid bulla; U = uncinate process; MT = middle turbinate; white line = infundibulum; star (*) = maxillary sinus ostium.

*University College Hospital London, London, UK.
†Imperial College NHS Trust, St. Mary's Hospital, London, UK.
Address reprint requests to: Timothy J. Beale, FRCR, FRCS, University College Hospital London, 235 Euston Road, London NW1 2BU, UK. E-mail: timothy.beale@royalfree.nhs.uk

0887-2171/09/$-see front matter
doi:10.1053/j.sult.2008.10.011

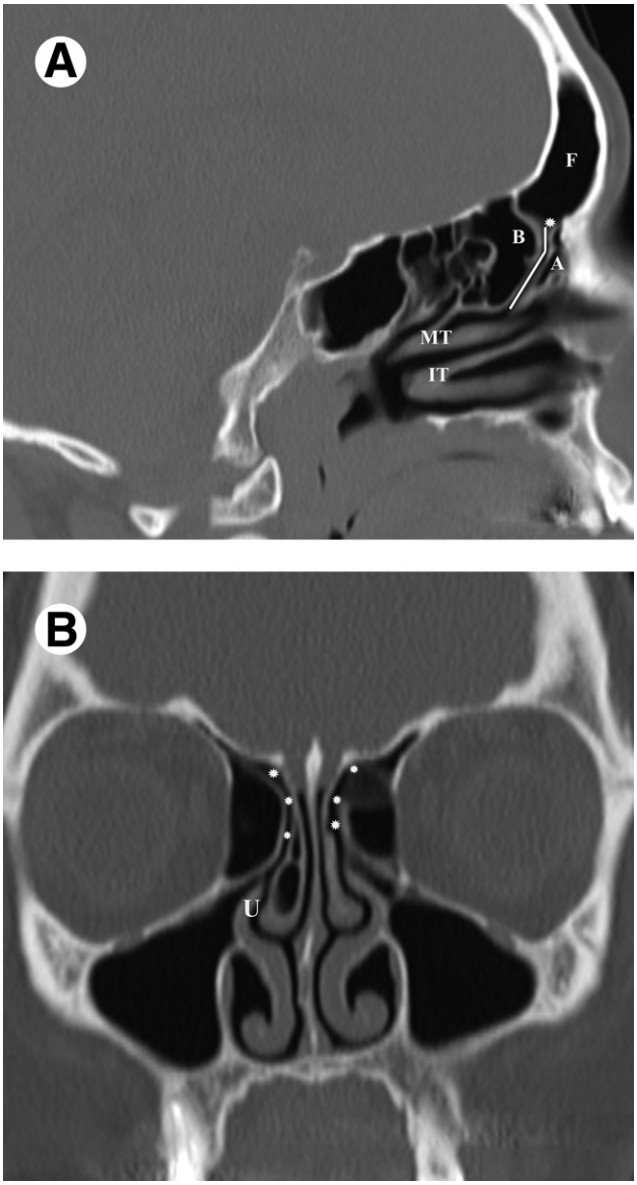

Figure 2 (A) Sagittal CT demonstrating the relations of the frontal recess (white line). F = frontal sinus; B = ethmoid bulla; A = agger nasi cell; star (*) = frontal sinus ostium; MT = middle turbinate; IT = inferior turbinate. (B) Coronal CT showing the usual drainage pattern of the frontal recess (*) into the middle meatus. U = uncinate process.

into the frontal bone (frontal sinus aplasia) in 5% and hypoplasia in 4%.[1] In another study frontal sinus aplasia was demonstrated in 8% of examinations.[2]

The anatomy of the frontal recess is complex and variable, not helped by the differing nomenclature found in the medical literature used to describe the accessory air cells found in this region. The classification for some of these air cells will be given below. However, the detailed description of the exact location of the accessory cell, its relationship to the drainage pathway (frontal recess and sinus ostium), and whether it is likely to contribute to the inflammatory sinus disease (or present a potential surgical hazard) is more useful than any classification system.

The frontal recess region is a potentially hazardous site for the surgeon due to the close relationship with the lamina papyracea, anterior skull base, and anterior ethmoidal artery. A common reason for endoscopic failure is inadequate removal of air cells obstructing the frontal sinus.[3] In order to minimize any surgical risk and achieve a surgical success, it is vitally important that the radiologist appreciates the variable anatomy and communicates the relevant information to the surgeon.

The frontal recess drains the frontal sinus and measures, on average, 13 mm in anterior to posterior diameter.[4] It has the shape of an inverted funnel whose apex is at the frontal ostium.[5] The recess is formed by the walls of the adjacent air cells, hence, the term recess rather than nasofrontal duct.

The usual boundaries of the frontal recess are as follows: anteriorly and inferiorly, the agger nasi air cell (ANC); posteriorly, the ethmoidal bulla; laterally, the lamina papyracea; medially, the lateral wall of the olfactory fossa and the middle turbinate; and superiorly, the fovea ethmoidalis (Fig. 2A and B). The sagittal reconstructed images are particularly useful for assessing the frontal recess due to its oblique orientation, at 50° to the orbito-meatal plane.

The Agger Nasi Air Cell

The ANC is the most constant and anterior of the ethmoidal air cells, hence the Latin term meaning nasal mound, and is located anterior to the vertical (anterior) attachment of the middle turbinate to the skull base. As it forms the anterior and inferior wall of the frontal recess, the surgical access to recess is via the ANC (Fig. 3).

The degree of ANC pneumatization varies and has a significant effect on both the size of the frontal sinus ostium and the shape of the recess. If the ANC is small, then the thick bone or "beak" of the frontal process of the maxilla, lying anteriorly and superiorly, will be prominent and extend posteriorly into the frontal recess, resulting in a narrow ostium.[6] Conversely, if the ANC is large, the beak will be small, resulting in a wider ostium but potentially causing obstruction more inferiorly (Fig. 4A-C).[7]

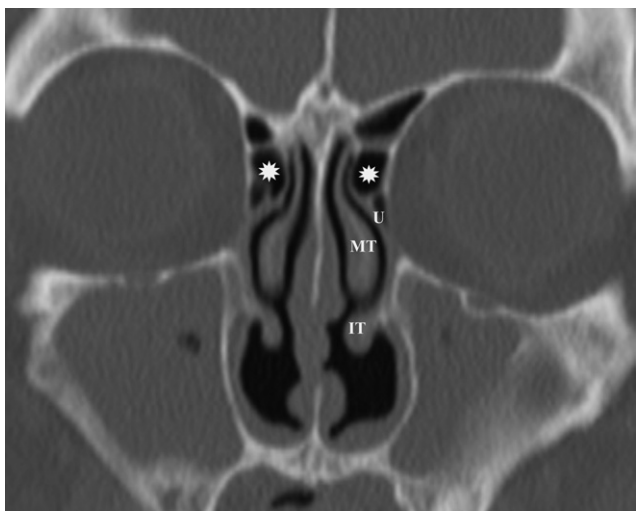

Figure 3 Coronal CT. The anterior uncinate process (U) most frequently attaches anteriorly to the agger nasi cell (ANC (*)) and lamina papyracea. MT = middle turbinate; IT = inferior turbinate.

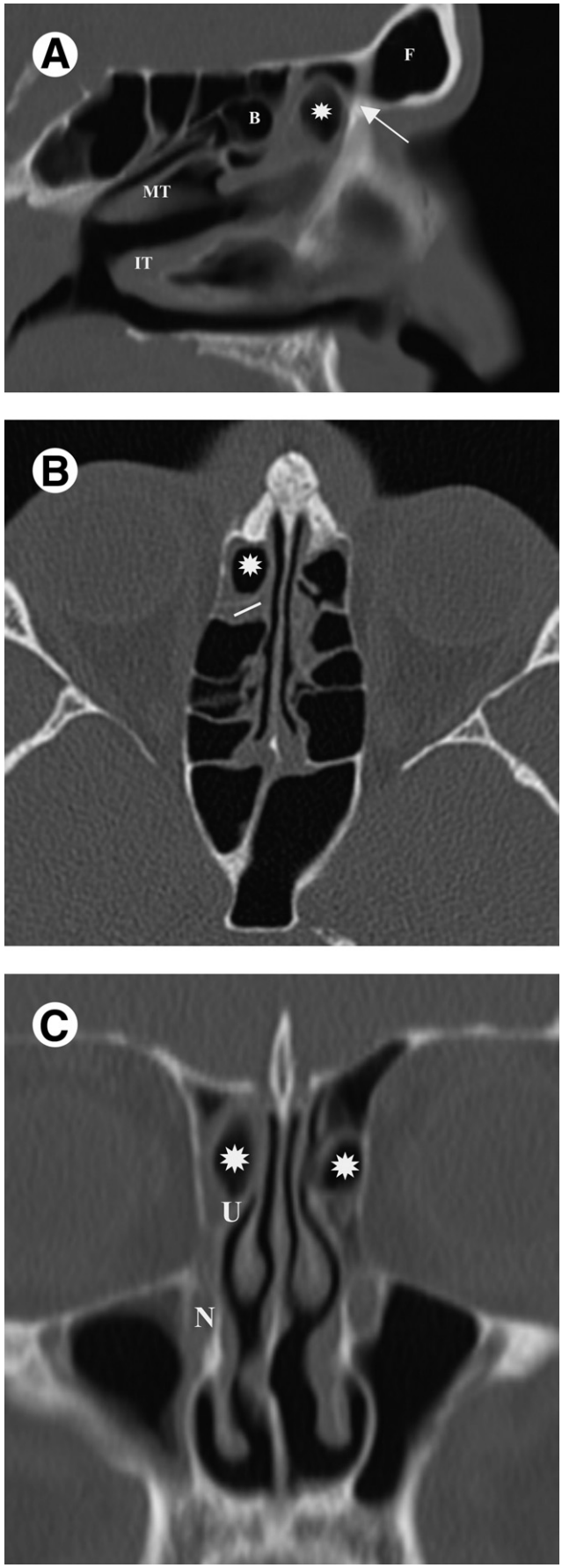

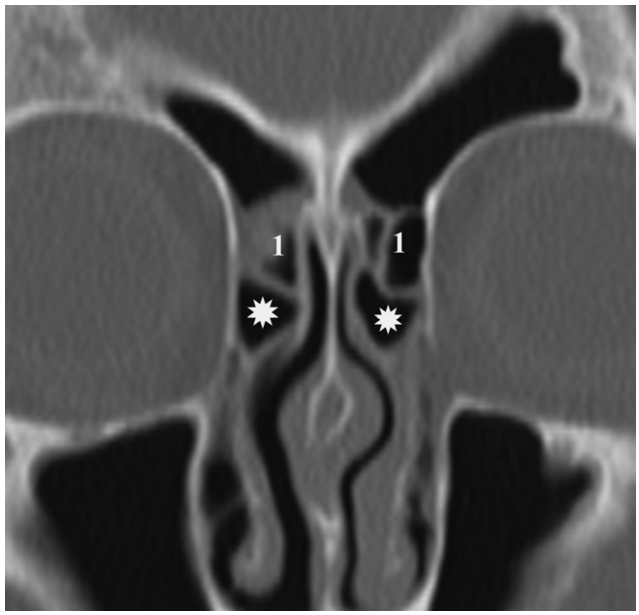

Figure 5 Coronal CT. The type 1 frontalethmoidal air cell is superior to the ANC (*) but does not extend into the frontal sinus.

This beak of bone represents the anterior floor of the frontal sinus and can be clearly seen on both sagittal and anterior coronal reformatted images. In the coronal plane it is seen as a continuous bony ridge and is useful for assessing whether an accessory air cell has extended into the frontal sinus.[6]

The Frontalethmoidal (Kuhn) Cells

There are various accessory air cells in the frontoethmoidal region that may or may not be present. It is important to work out the drainage pathway of the frontal sinus around these cells.

Frontalethmoidal air cells, also known as Kuhn air cells,[8] are categorized into four types depending on their number and degree of extension into the frontal sinus.[6] They are all located superior to the ANC.

Type 1 (most common): Single cell superior to the ANC that does not extend into the frontal sinus (ie, remains below the "beak") (Fig. 5).

Type 2: Two or more cells superior to the ANC that may or may not extend into the frontal sinus (see Fig. 7).

Type 3: Single frontal cell superior to the ANC that extends into the frontal sinus (Fig. 6A and B).

Type 4: Completely contained in the frontal sinus. This configuration is rare (if assessed in three planes, a connection with an ethmoidal air cell can usually be demonstrated).

Figure 4 (A) Sagittal CT demonstrating a large partially opacified ANC (*) displacing the frontal recess posteriorly. Note the small frontal beak (white arrow). F = frontal sinus; B = ethmoid bulla; MT = middle turbinate; IT = inferior turbinate. (B) Axial CT highlighting the narrowed posteriorly displaced frontal recess (white line) secondary to the enlarged ANC (*). (C) Coronal CT. Again the enlarged ANC (*) narrowing the frontal recess. U = uncinate process; N = nasolacrimal canal.

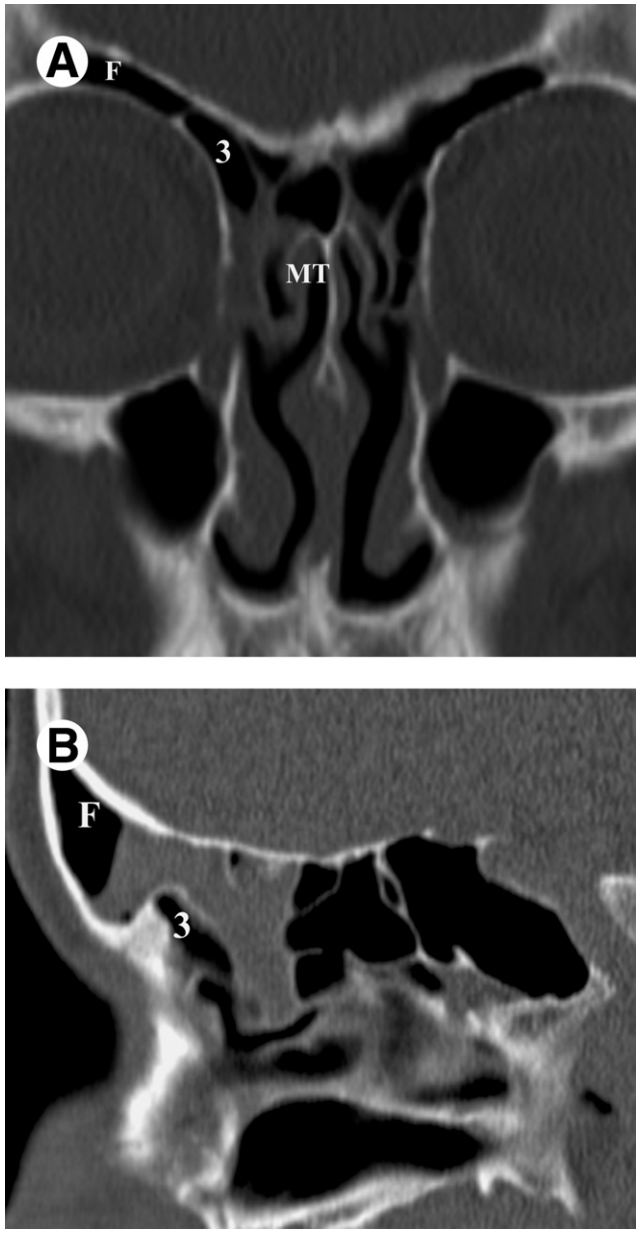

Figure 6 Coronal (A) and sagittal (B) CT: The type 3 frontalethmoidal cell (3) extends into the frontal sinus. F = frontal sinus; MT = middle turbinate. Note the obstructed frontal recess. If frontal sinus drainage is being considered, it is important to inform the surgeon of this accessory air cell.

These cells lie superior to the ANC. Once the ANC has been opened at operation, the configuration of these cells dictates the approach to the frontal recess. Types 1-3 frontoethmoidal cells may need to be excised in order to open the frontal recess and adequately drain the frontal sinus.

Other Accessory Air Cells in the Frontal Sinus Region

Other anterior ethmoidal air cells that may form the boundary of the frontal recess have been described such as the supraorbital, suprabulla, and frontal bulla cells.

The supraorbital cell, usually anterior ethmoidal in origin,

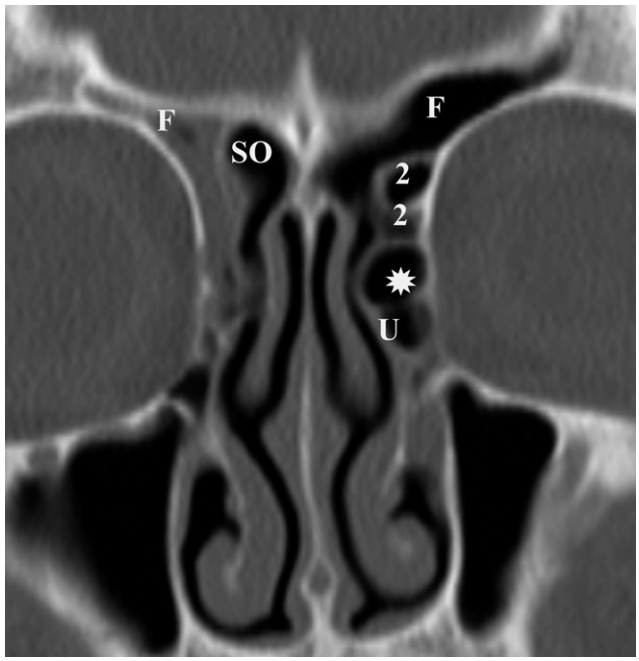

Figure 7 Coronal CT. The supraorbital air cell (SO) extends medial and superior to the frontal sinus. Note also the multiple type 2 frontalethmoidal cells (2) on the contralateral side. F = frontal sinus; * = agger nasi cell; U = uncinate process.

extends into the orbital plate of the frontal bone often medial and superior to the frontal sinus and is usually bilateral (Fig. 7). The frontal bulla cell is a superior extension of the ethmoidal bulla into the frontal recess region. The suprabulla air cell is an additional air cell just superior and anterior to the ethmoidal bulla (Fig. 8). Finally there may be an air cell within the intersinus septum of the fontal sinus (Fig. 9). All these cells may alter the shape and position of the frontal recess or frontal sinus ostium. However, radiologists should only use these terms in the context of the frontoethmoidal drainage, if they are used and understood by their clinical colleagues.

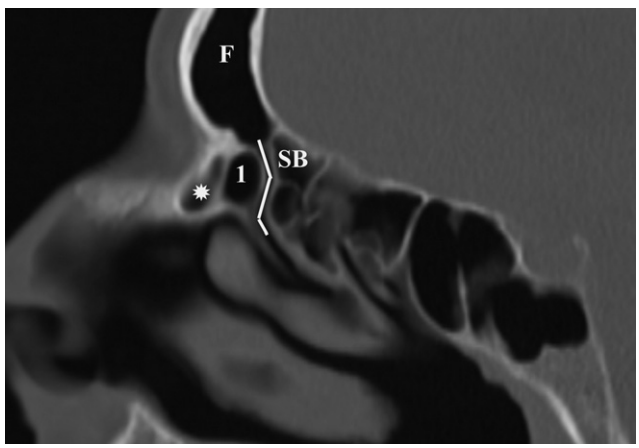

Figure 8 Sagittal CT. The suprabulla cell (SB) extends superior to the small ethmoidal bulla. Note also the type 1 frontalethmoidal cell (1). F = frontal sinus; * = agger nasi cell; white line = frontal recess.

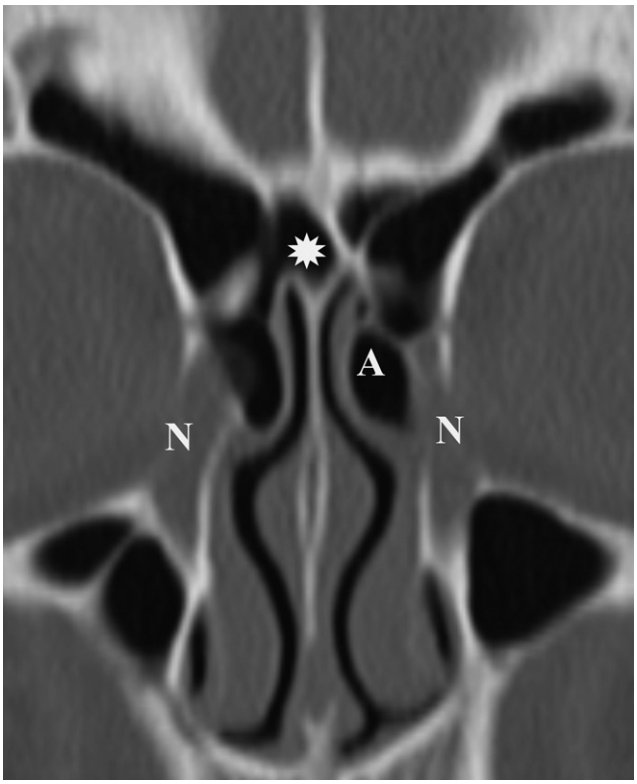

Figure 9 Coronal CT. The star highlights the extension of the right frontal sinus into the anterior intersinus septum. A = agger nasi cell; N = nasolacrimal canal.

It is vital to routinely review sinonasal CT scans in three planes. Multiplanar reformatted images in the sagittal plane are particularly helpful. In fact it is not possible to fully assess the anatomy without reference to the reformatted images. Remember that incomplete removal of air cells forming the boundaries of the recess is the most frequent cause of continued symptoms following surgery.[7]

The Uncinate Process and Ethmoid Infundibulum

The frontal recess opens into either the ethmoid infundibulum or the middle meatus, depending on the superior attachment of the uncinate process.[4] The uncinate process is a crescent-shaped bone and a key component of the OMU and may vary considerably in size. It is a key landmark for the surgeon and uncinectomy is usually the initial procedure in endoscopic sinus surgery in order to open up (visualize) the maxillary sinus ostium.

The relations of the uncinate process are as follows: anteriorly and superiorly, the frontal recess and inferiorly (the ethmoidal process of) the inferior turbinate. Posteriorly, the uncinate bone has a free superior edge that forms the inferior margin of the hiatus semilunaris, the superior margin of the hiatus being the ethmoidal bulla (Fig. 1).

The variable anterosuperior attachment of the uncinate process impacts on the frontal recess drainage.

Commonly the uncinate process attaches anteriorly to the lamina papyracea and agger nasi air cell with the frontal recess draining into the middle meatus (Fig. 10A-D). In this situation obstruction of the ethmoid infundibulum will usually not result in frontal sinusitis. The uncinate process may be displaced medially by a large ANC and attach to the middle turbinate. This displaces the frontal recess posterior to the ANC (Fig. 4B). In this situation the frontal drainage pathway can only be accessed at endoscopy, by fracturing the posterior wall of the ANC.

Rarely the uncinate process may extend superiorly to the skull base without touching the ANC with the frontal recess draining into the ethmoid infundibulum (Fig. 11). In this situation ethmoid infundibular obstruction may also result in frontal sinusitis.

Due to its variable attachment, uncinectomy may result in damage to the skull base and lamina papyracea.

Variations in Uncinate Process Configuration

The atelectatic uncinate process opposes or may even be fused to the junction of floor and medial wall of the orbit. This is usually associated with a hypoplastic and opacified antrum, which may be associated with descent of the orbital floor, increasing the risk of trauma to the orbit (Fig. 12).

The atelectatic uncinate process can also be seen with an "imploding" or "silent" sinus where all the walls of the antrum are concave inwards secondary to negative pressure[9] (Fig. 13A-C).

The horizontal or vertical orientation of the uncinate process is dictated by adjacent structures: the ethmoidal bulla, middle turbinate, and nasal septum, which affects the anterior OMU drainage. The horizontal uncinate process is almost always associated with an enlarged ethmoidal bulla[1] (Fig. 14). The uncinate process may also be hooked or pneumatized (Fig. 15A and B).

The Ethmoidal Bulla

The ethmoidal bulla is an anterior ethmoidal air cell of variable size located just posterior to the free edge of the uncinate process. The opening between the anterior surface of the bulla and the free edge of the uncinate process is the hiatus semilunaris and the passageway between the two is the ethmoid infundibulum (Fig. 16A and B).

When the bulla extends to the skull base, its anterior wall forms the posterior boundary of the frontal recess. However, when it does not extend to the skull base, there is a suprabulla recess (Fig. 17A and B).

An enlarged ethmoidal bulla may compromise the outflow of both the maxillary antrum and the frontal sinus by distorting the ethmoid infundibulum/hiatus semilunaris and the frontal recess, respectively (Fig. 18).

The ostium of the bulla is usually located on the posterior wall, which may be partially fused to or separated from the basal lamella (see below) by the retrobulbar recess (sinus lateralis).

The Nasal Turbinates

Three turbinates (rarely four) project into the nasal cavity. The inferior and superior turbinates have no significant anatomical variations as they have little impact on drainage.

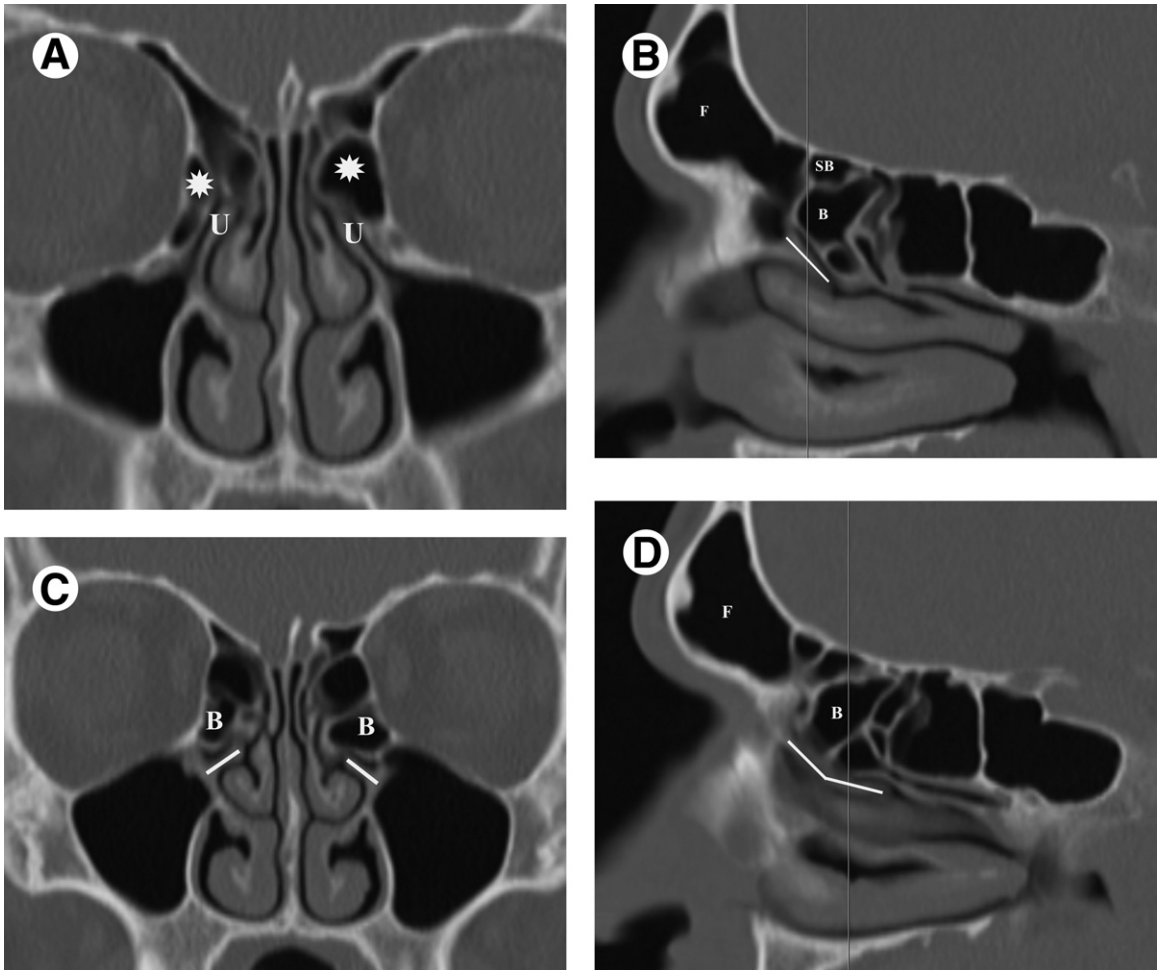

Figure 10 (A) Coronal CT. Note the asymmetry in size of the agger nasi cells (*) and the attachment of the uncinate process (U). (B) Sagittal CT. The vertical line corresponds to coronal CT image (A). The uncinate process is highlighted (white line). The ethmoid infundibulum is the space and the hiatus semilunaris the opening between the uncinate process and the ethmoidal bulla (B). F = frontal sinus; SB = suprabulla cell. (C) Coronal CT. Note the more horizontal position of the uncinate processes (U) secondary to the prominent ethmoidal bullae (B). (D) Sagittal CT. Vertical line corresponding to coronal image (C). White line = uncinate process; F = frontal sinus; B = ethmoidal bulla.

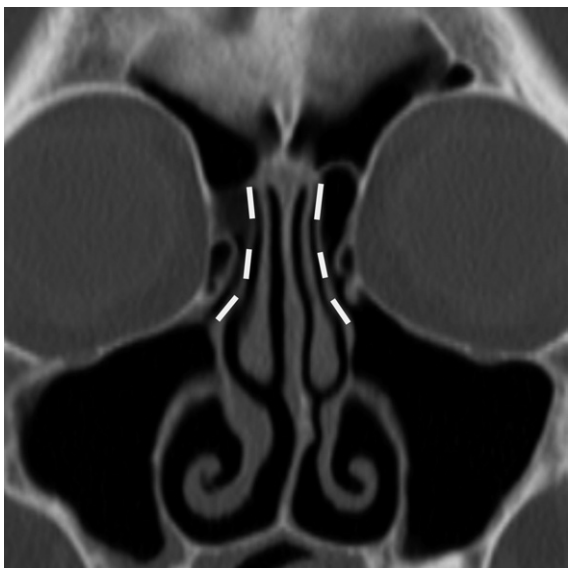

Figure 11 Coronal CT demonstrating attachment of the UP (interrupted line) to the anterior skull base. The frontal recess therefore drains lateral to the UP into the ethmoid infundibulum.

Figure 12 Coronal CT. Note the bilateral hypoplastic antra (A) and atelectactic UP (white line).

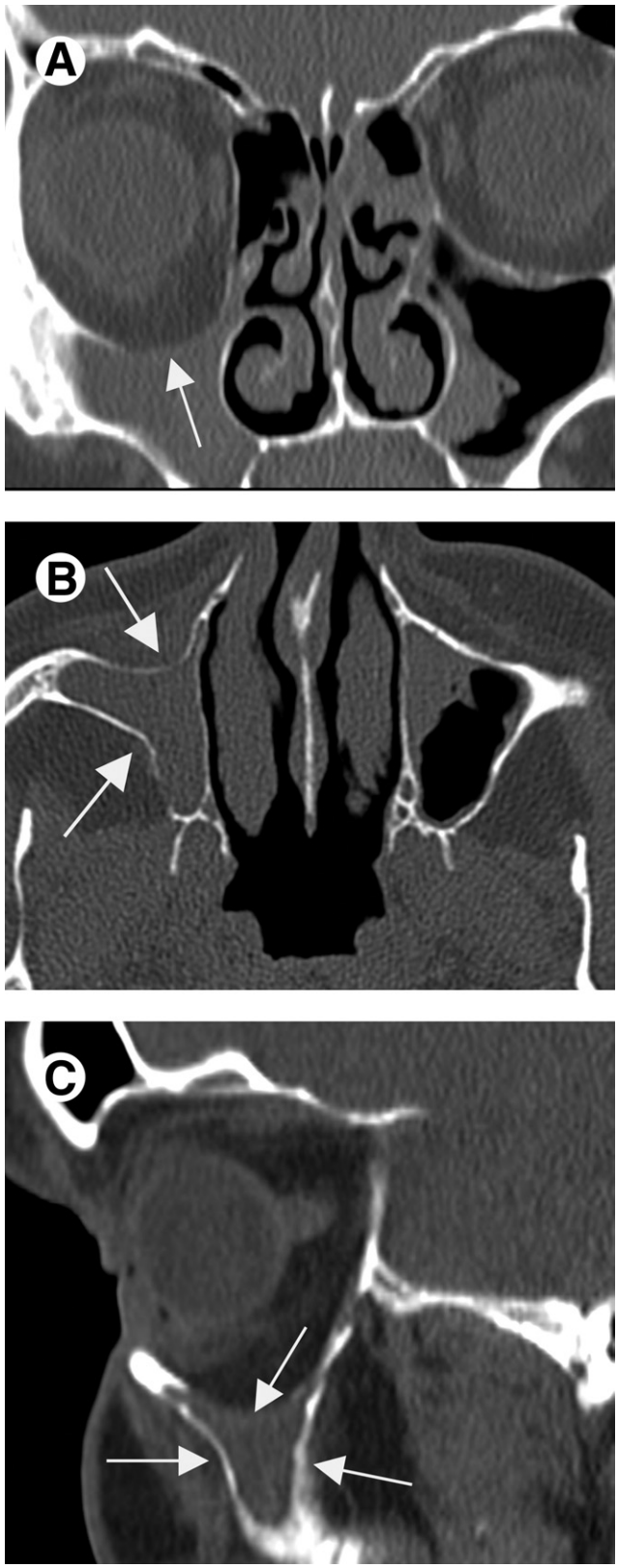

Figure 13 Coronal (A), axial (B), and sagittal (C) CT showing the inward concavity of all walls of the imploding right antrum (white arrows). The descent of the orbital floor seen in (A and C) may lead to enopthalmos and must be noted prior to any corrective surgery.

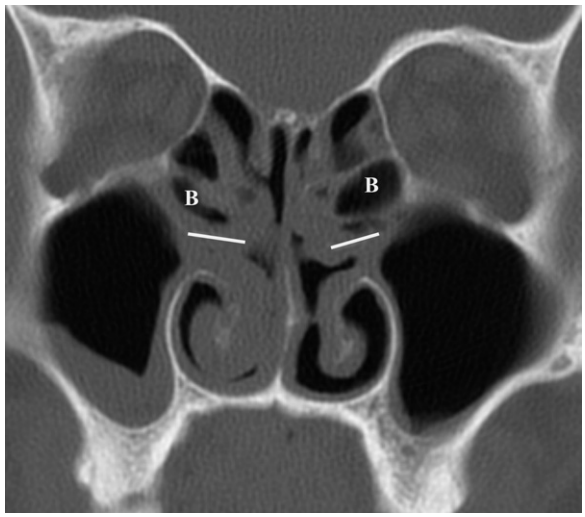

Figure 14 Coronal CT highlighting the displaced, horizontally positioned UP (white line) secondary to the bilateral enlarged ethmoid bullae (B).

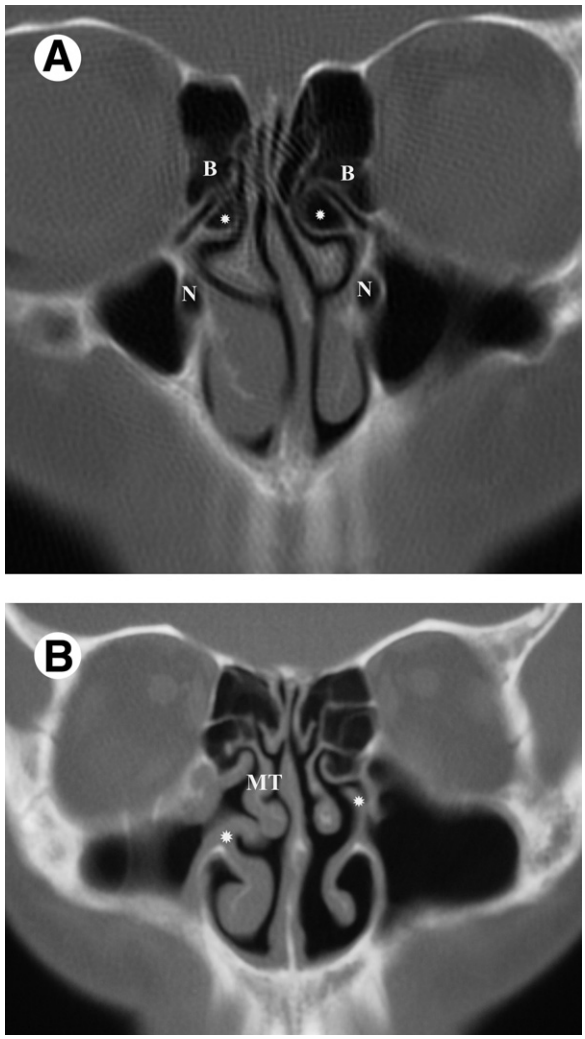

Figure 15 (A) Coronal CT. Bilateral pneumatized UP (*) may narrow the ethmoid infundibulum and middle meatus. B = ethmoid bulla; N = nasolacrimal canal. (B) Coronal CT. Hook-like right-sided UP (*) associated with a paradoxical turn to the adjacent MT. Compare to the normally positioned left UP (*).

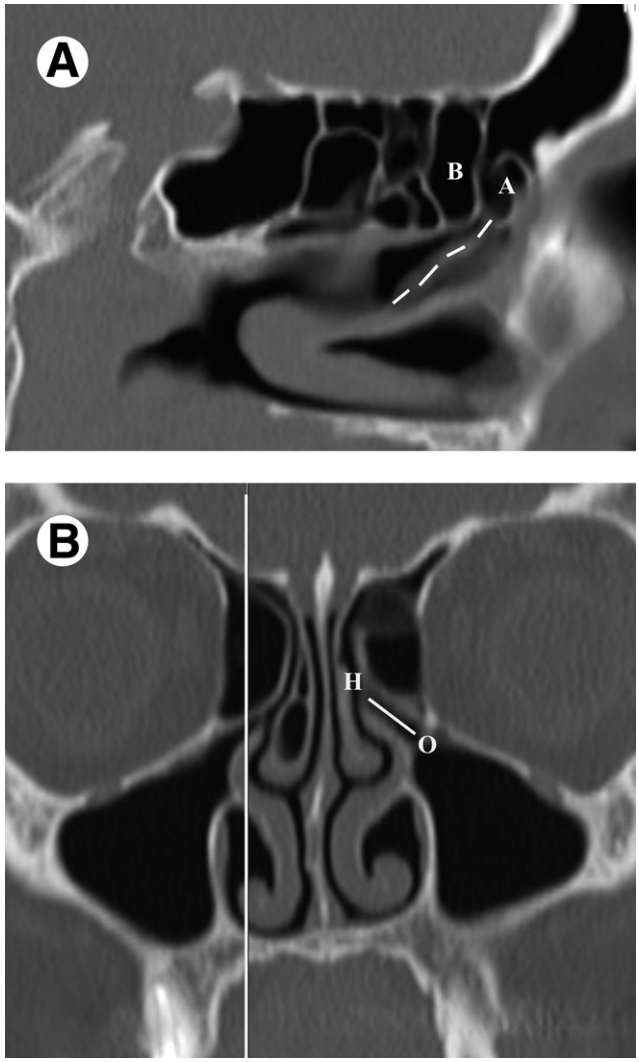

Figure 16 (A) Sagittal CT demonstrating part of the UP (interrupted white line) attached to the agger nasi cell (A) anteriorly. Between the ethmoid bulla (B) and UP is the ethmoid infundibulum and hiatus semilunaris. The frontal recess passes between the bulla (B) and the agger nasi cell (A). (B) Coronal CT. The vertical line corresponds to the sagittal image (A). The ethmoid infundibulum is highlighted (white line) as is the sinus ostium (O) and hiatus semilunaris (H).

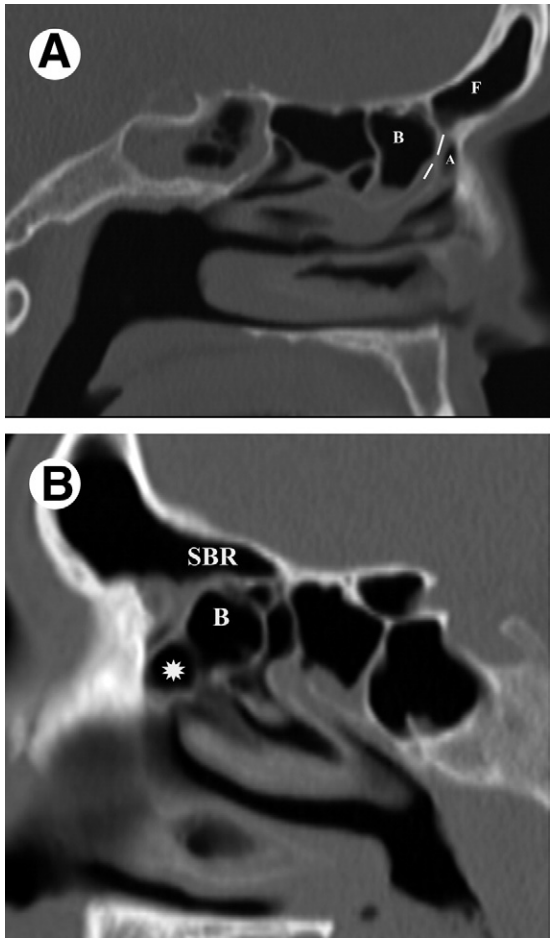

Figure 17 Sagittal CT. (A) The frontal recess (interrupted white line) is displaced anteriorly and narrowed by the large ethmoid bulla (B). A = agger nasi cell; F = frontal sinus. Note also secretions in the sphenoid but a clear sphenoethmoidal recess. (B) The suprabullar recess (SBR) is shown extending superior to the ethmoid bulla (B). The ethmoidal artery is therefore at risk as it passes through the posterior aspect of the SBR. The frontal recess passes between the ANC (*) and the ethmoid bulla (B).

Variations of the middle turbinate are common and impact on the anterior OMU drainage. The middle turbinate attaches superiorly to the anterior skull base and posteriorly to the lamina papyracea. This posterior attachment is called the basal or ground lamella and has an oblique course. It is an important surgical landmark and marks the boundary between the anterior and posterior ethmoidal air cells (Fig. 19A and B). The space between the basal lamella and the ethmoidal bulla is called the sinus lateralis (retrobulbar recess).

The Common Middle Turbinate Variants are Listed as Follows

Concha Bullosa

Pneumatization of the inferior bulbous portion of the turbinate is called a concha bullosa, is usually bilateral, and occurs

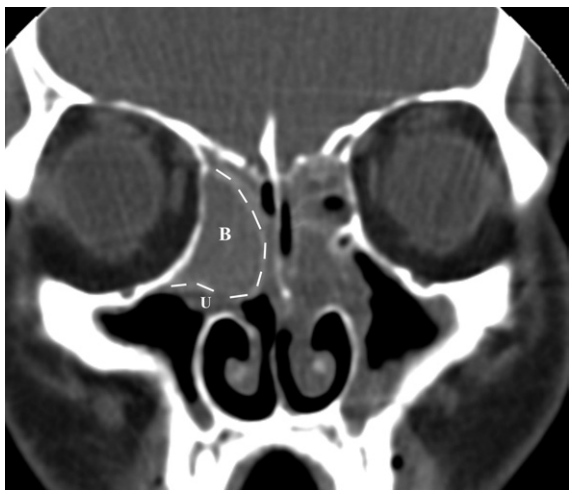

Figure 18 Coronal CT. Note the very large opacified right ethmoid bulla (B) (interrupted white line) displacing the UP inferiorly (U) and compromising the outflow of both the frontal sinus and maxillary antrum.

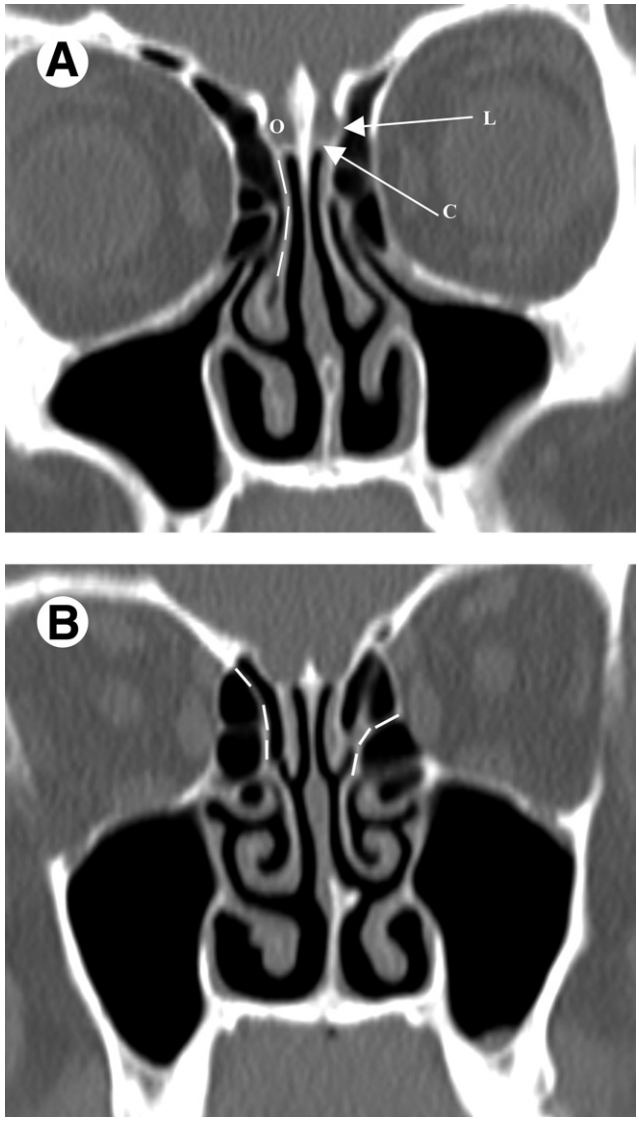

Figure 19 (A and B) Coronal CT demonstrating the anterior attachment of the MT (interrupted white line) in (A) to the anterior skull base. O = olfactory fossa; C = cribriform plate; L = lateral lamella and in (B) the more posterior attachment of the basal or ground lamella (interrupted white line) to the lamina papyracea. Both the anterior skull base and the lamina papyracea are at risk of trauma during surgery to the MT.

in 24-55% of the population.[1,10,11] If the pneumatization is above the level of the OMU complex, it is called a lamella cell or a conchal neck air cell. Although small, the bullosa is not clinically significant; a large concha bullosa, which is usually associated with septal deviation, may obstruct the drainage pathway of the antrum by distorting the uncinate process and narrowing the infundibulum (Fig. 20).

Paradoxical Turn

The middle turbinate may have a lateral convexity (a paradoxical turn) and is present in approximately 26% of people.[12] Again small paradoxical turbinates are not clinical significant but, if large, are frequently associated with septal deviation and may impair access to the OMU (Fig. 21).

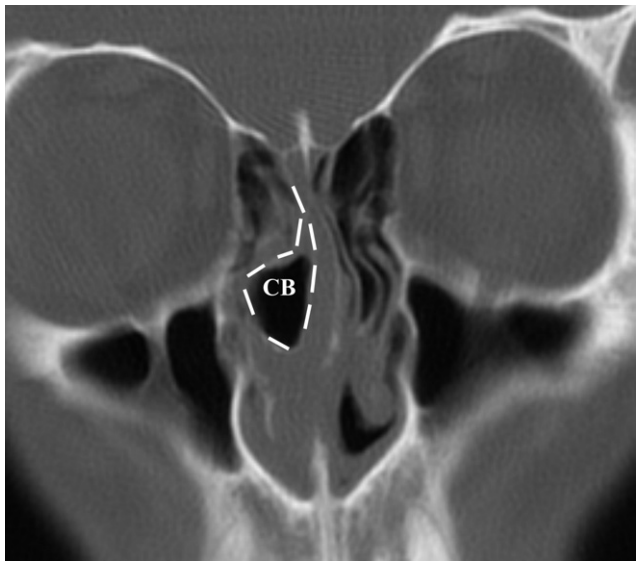

Figure 20 Coronal CT. The large concha bullosa (CB) (interrupted line) of the right MT compromises the outflow of the right antrum and frontal sinus (recess) and is associated here with septal deviation to the left.

Infraorbital (Haller) Air Cells

There are various definitions and therefore varied reported frequencies (of up to 45%) of infraorbital air cells in the literature.[13,14] They are centered inferior to the ethmoidal bulla and grow into the floor of the orbit. They may narrow the maxillary sinus ostium, especially if infected (Fig. 22).

Maxillary Sinus (Anatomical Variants)

The anatomical variants of the maxillary sinus are sinus septations, the accessory sinus ostium, and the sinus hypoplasia. The normal maxillary sinus (or recesses) may extend into the palate, infraorbital region, and maxillary alveolus (Fig. 23).

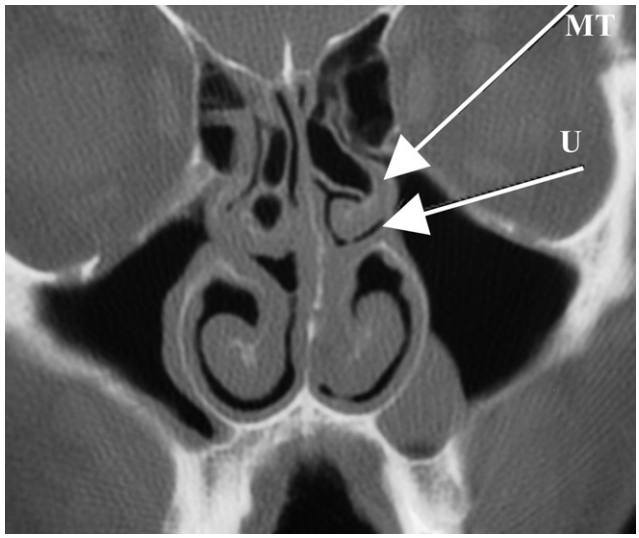

Figure 21 Coronal CT. The combination of the paradoxical turn and bullosa of the lamella of the left MT is displacing the uncinate process (U).

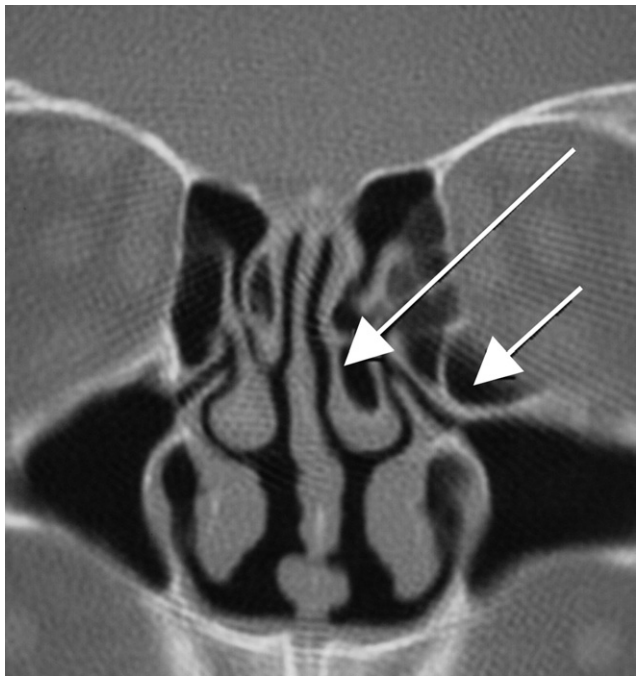

Figure 22 Coronal CT. The larger more superior arrow highlights the concha bullosa of the MT and the smaller arrow the infraorbital (or Haller) air cell. Infraorbital air cells may compromise the outflow of the antrum especially when inflamed.

The maxillary sinus septum may be fibrous or bony and often extends from the infraorbital canal to the lateral wall and if not recognized may lead to inadequate drainage of the antrum (Fig. 24A and B).[10]

The accessory ostium or posterior fontanelle is located posterior to the natural ostium and is present in approximately 10% of the population.[15] It is important to identify as antrochoanal polyps may extend through the accessory sinus ostium rather than the natural ostium (Fig. 25A-C). In addition there is occasionally a circular flow of mucus from the natural ostium inferiorly into the accessory ostium, leading to recurrent sinusitis. If recognized, the accessory ostium should be surgically joined to the natural ostium.[6]

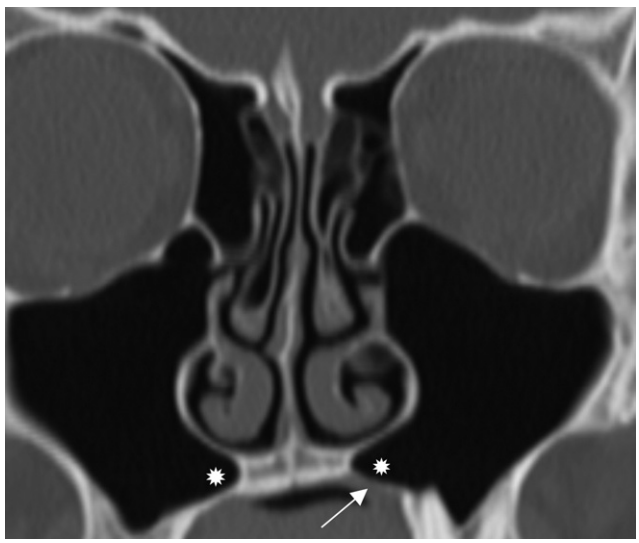

Figure 23 Coronal CT. Demonstrating extension of the antrum inferior to the floor of the nasal cavity (palatine recess (*)). Note the thinned bone of the left side of the hard palate (arrow).

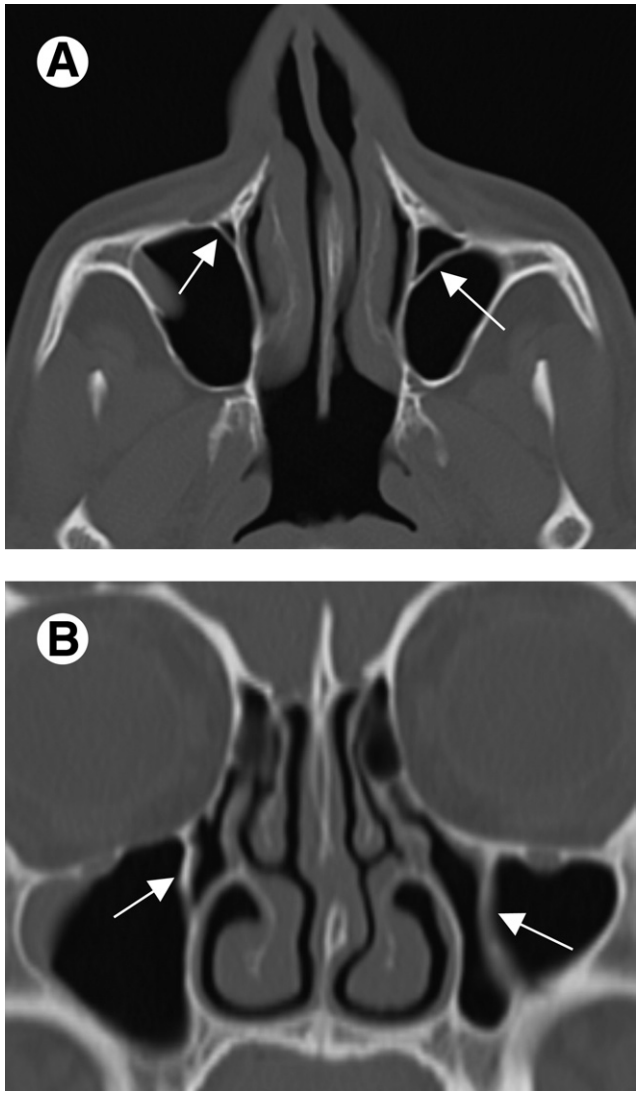

Figure 24 Axial (A) and coronal (B) CT demonstrating a bony septation within the antrum (arrows).

Previous sinus Caldwell-Luc surgery and the silent sinus may mimic maxillary sinus hypoplasia by reducing the volume of the antrum. Rarely there may be sinus asymmetry secondary to a cranio-facial anomaly but sometimes no underlying cause is demonstrated. The main risk in maxillary sinus hypoplasia is inadvertent entry into the orbit, during endoscopic surgery, through either the lamina papyracea or the floor.

The Nasal Septum

The components of the nasal septum are the septal cartilage anteriorly and the vomer and perpendicular plate of the ethmoid posteriorly (Fig. 26). The anatomic variations of the nasal septum are septal deviation (which may be developmental or acquired), septal spur, and pneumatization.

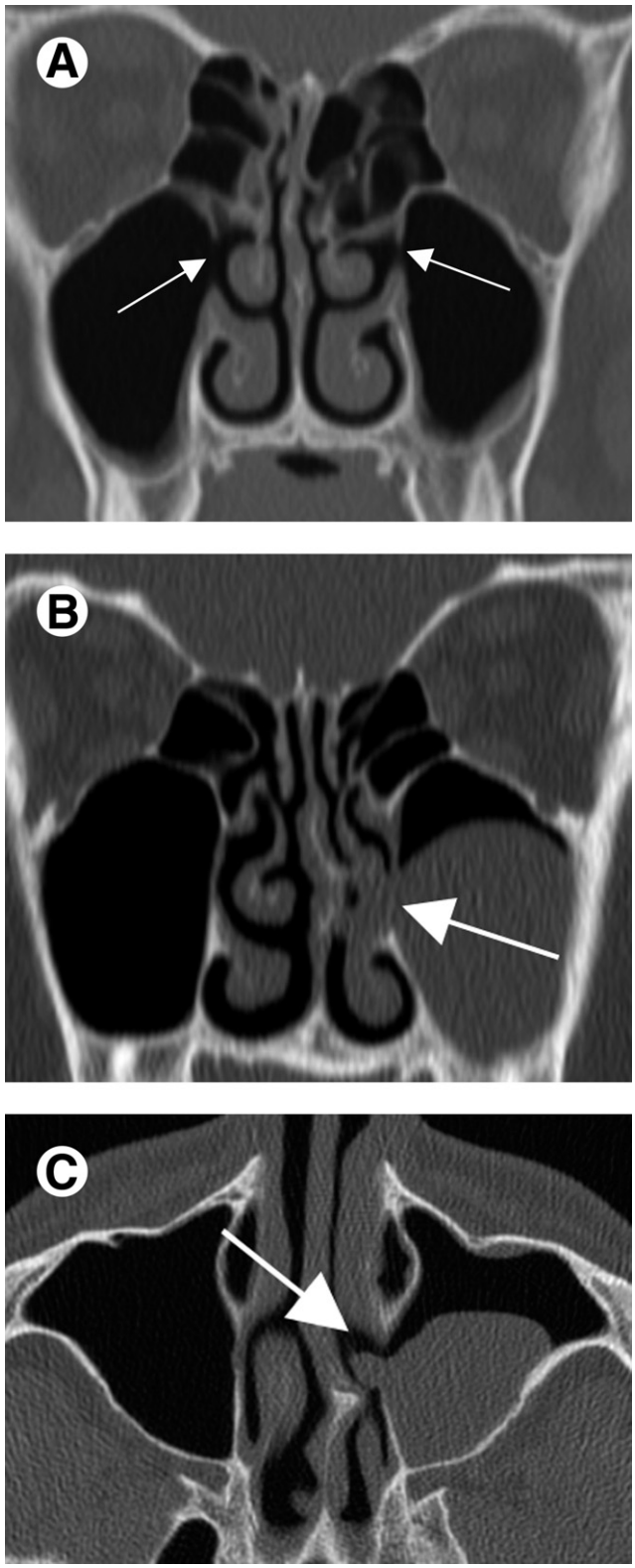

Figure 25 (A) demonstrates an accessory sinus ostium (white arrow) on each side (there may be more than one). (B) (coronal) (C) (axial CT) demonstrating an antral polyp extending through the accessory ostium (white arrow) rather than the more usual sinus ostium and ethmoid infundibulum.

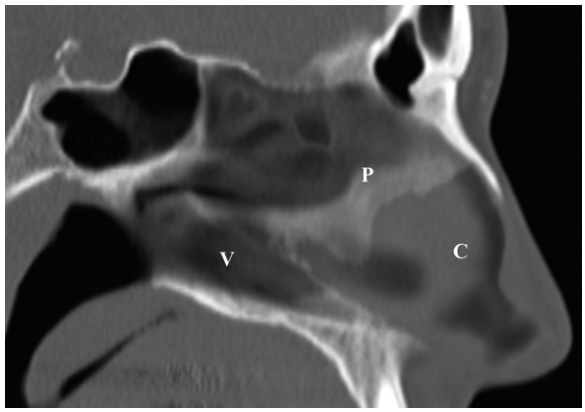

Figure 26 Sagittal CT highlighting the three components of the nasal septum: the perpendicular plate of the ethmoid (P), the vomer (V), and the more anterior nasal cartilage (C).

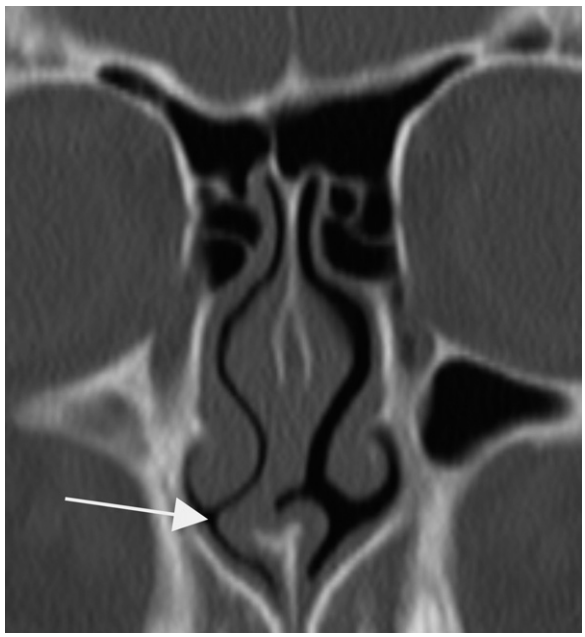

Figure 27 Coronal CT with deviation of the septum at the chondro-vomeral junction (white arrow).

Figure 28 Coronal CT. Note the prominent septal spur (white arrow) abutting the lateral wall of the nasal cavity.

The incidence of septal deviation is varied 20-79%[6,10] and is often not clinically relevant. However septal deviation can displace the middle turbinate, narrowing the middle meatus, making surgical access difficult.

The septum may be focally deviated inferiorly at the chondrovomeral junction (Fig. 27) or have a more broad-based curvature often associated with a concha bullosa of the middle turbinate (Fig. 20).

Septal spurs are frequently encountered in association with septal deviation and if prominent may also make surgical access difficult and narrow the middle meatus or ethmoidal infundibulum (Fig. 28).

The pneumatized septum is usually due to extension of air from the sphenoid sinus or crista galli and is usually not significant but may narrow the sphenoethmoidal recess (Fig. 29).

The Posterior Ethmoidal Air Cells and the Sphenoid Sinus

The sphenoid sinus drains via the sphenoid sinus ostium, located between one-third and halfway up the medial aspect of the anterior wall, and from there into the sphenoethmoidal recess (Fig. 30A and B). The posterior ethmoidal air cells drain via individual ostia into the superior meatus.

The posterior ethmoidal air cells may variably extend superior to the sphenoid sinus (located between the sphenoid sinus and skull base), pushing the sphenoid sinus inferiorly and forming the sphenoethmoidal air cell (Onodi cell). The sphenoethmoidal air cell is important to identify due to its direct inferomedial relation to the optic nerve (Fig. 31). Although the parasagittal reformatted images are the most helpful at differentiating the sphenoid sinus from a posterior ethmoidal air cell, there is a useful clue to the presence of sphenoethmoidal air cells on the coronal images: if the air cell superior to the posterior choanae (usually the sphenoid) contains a horizontal or cruciform septation, it signifies uni- or bilateral sphenoethmoidal air cells. The horizontal septum is caused by horizontal displacement of the anterior wall of the sphenoid by a more superior sphenoethmoidal air cell and the cruciform sign is present if there are two sphenoethmoidal cells with a midline vertical septum (Fig. 32).

Identification of the sphenoethmoidal air cell is important for the endoscopist. One endoscopic approach to the sphenoid sinus ostium is via the posterior wall of the posterior ethmoid air cells. However, when the sphenoethmoidal air cell is present, its posterior wall is the bone of the central skull

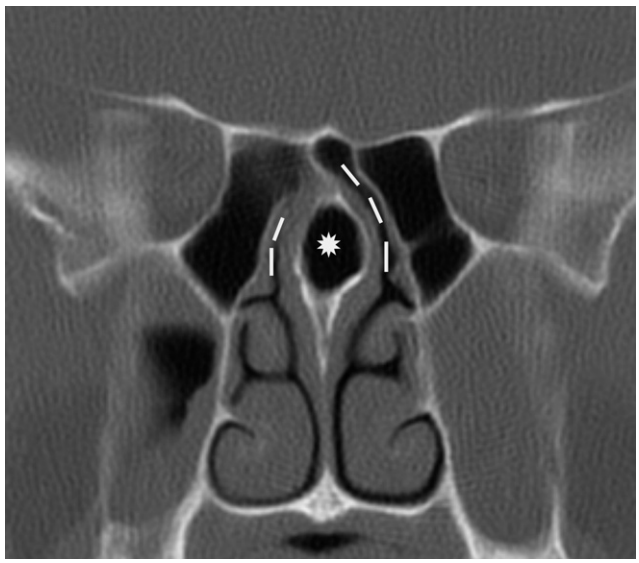

Figure 29 Coronal CT showing extension of the right side of the sphenoid into the posterior nasal septum (*) narrowing the sphenoethmoidal recesses (interrupted white lines) and making surgical access to the sphenoid sinus ostium difficult.

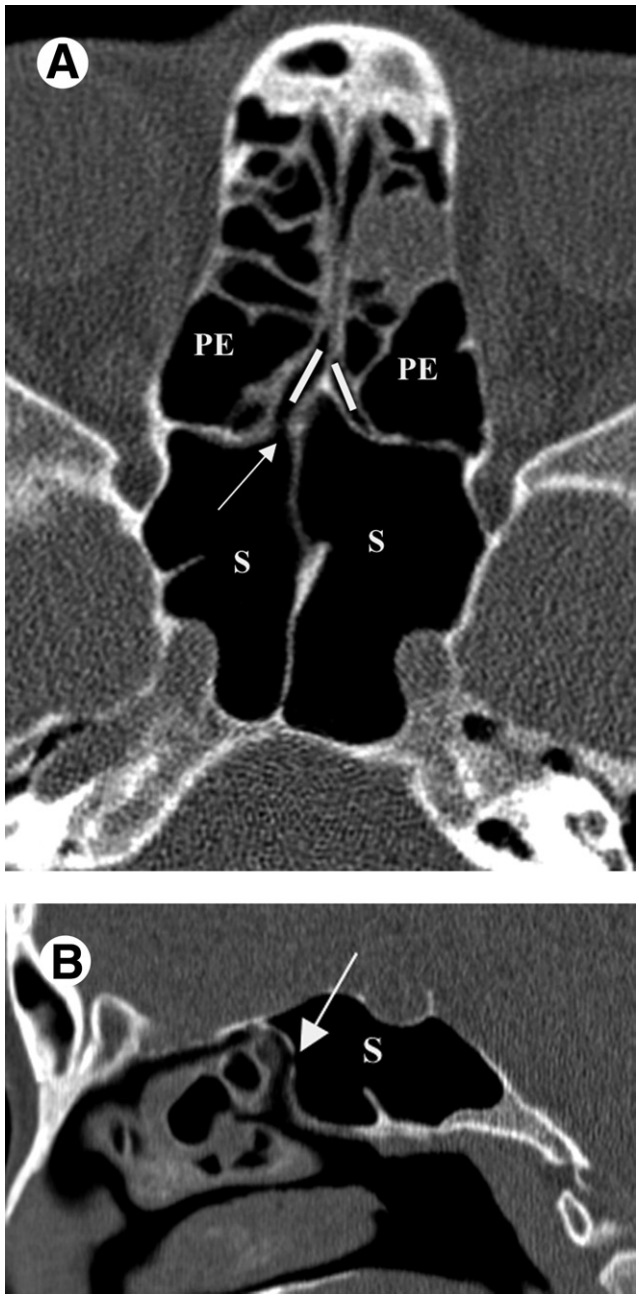

Figure 30 Axial (A) and coronal (B) CT showing the sphenoid sinus ostium (white arrow) and the sphenoethmoidal recess (white line). PE = posterior ethmoid; S = sphenoid sinus.

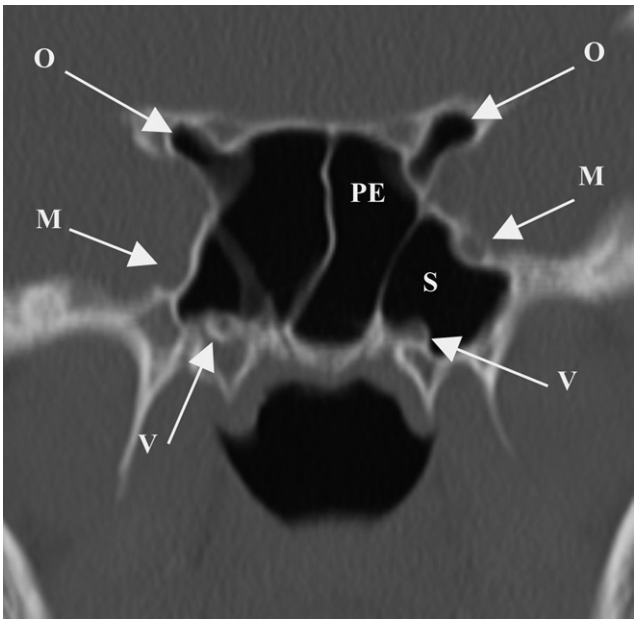

Figure 31 Coronal CT demonstrating bilateral onodi cells (O) secondary to extension of the posterior ethmoid cell superior to the sphenoid sinus into the anterior clinoid process immediately inferior to the optic nerve. PE = posterior ethmoid; S = sphenoid sinus; M = maxillary division in foramen rotundum; V = vidian canal.

base. Access to the posterior ethmoidal air cells should then be made by penetrating the basal (ground) lamella. If the sphenoethmoidal recess and sinus ostium need inspecting, it is important to dissect medially, by displacing the superior turbinate, rather than dissecting laterally through the posterior ethmoidal air cells, which places the optic nerve at risk.

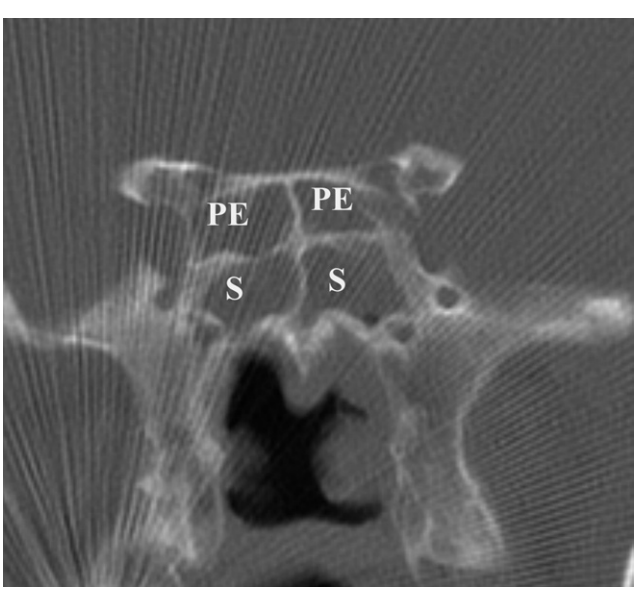

Figure 32 Coronal CT demonstrated the cruciform appearance of the sphenoethmoidal region on the same coronal plane as the choanae secondary to posterior extension of the posterior ethmoidal air cells (PE) superior to the sphenoid (S).

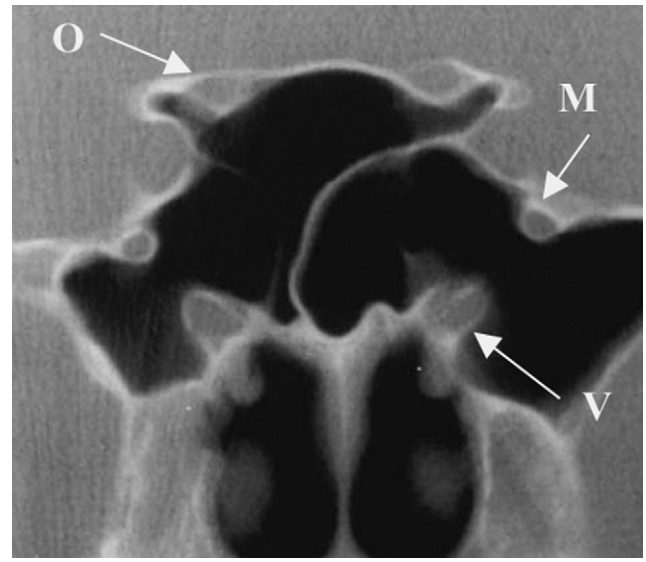

Figure 33 Coronal CT highlighting three of the structures that are closely associated with the walls of the sphenoid sinus and may be dehiscent and therefore at risk during surgery to this region. O = optic nerve; M = maxillary division 5th nerve; V = vidian canal.

Pneumatization of the anterior clinoid process, surrounding the optic nerve, occurs in 6-13% of cases.[10,14]

The optic nerve is usually closely related to the sphenoid rather than a posterior ethmoidal air cell; the bony covering is dehiscent in up to 24% of cases.[16]

Other structures that are closely related to the walls of the sphenoid sinus and indeed may project into the sinus and have dehiscent bony coverings are the cavernous segment of the internal carotid artery, the maxillary nerve, and the vidian canal (Fig. 33). All these structures are therefore at risk during sphenoid surgery and sphenoid sinus pathology may be associated with trigeminal neuralgia.

Ethmoid Roof and Anterior Skull Base

The roof of the ethmoidal air cells (fovea ethmoidalis) is higher than the more medial roof of the nasal cavity (or niche) formed by the cribriform plate. The olfactory fossa is the space between superior to the cribriform plate and has a variable depth. When the olfactory fossa is deep, there is a greater differential in height between the fovea and cribriform plate and the tall lateral wall of the olfactory fossa (lateral lamella) is at risk of surgical trauma (Fig. 34A and B).

A low skull base reduces the height of the ethmoidal air cells; the surgeon may wrongly suppose that there are more superior ethmoidal air cells present that require opening and inadvertently enter the anterior cranial fossa.

Asymmetry in height of the ethmoid roof also predisposes to inadvertent surgical trauma.

The anterior ethmoidal artery passes from the orbit, runs across the ethmoidal roof, and pierces the lateral lamella to reach the olfactory fossa. It is usually centered behind the ethmoidal bulla. However, if the ethmoidal bulla does not extend to the skull base and there is a suprabullar recess (Fig.

17A and B), the artery may be exposed and travel on a mesentery and be at risk of injury.

The anterior ethmoidal canal should be identified on coronal images (Fig. 35). It is important to note whether the artery is closely applied to the skull base, has a bony covering, is on a mesentery, or if the suprabullar recess is present.[17]

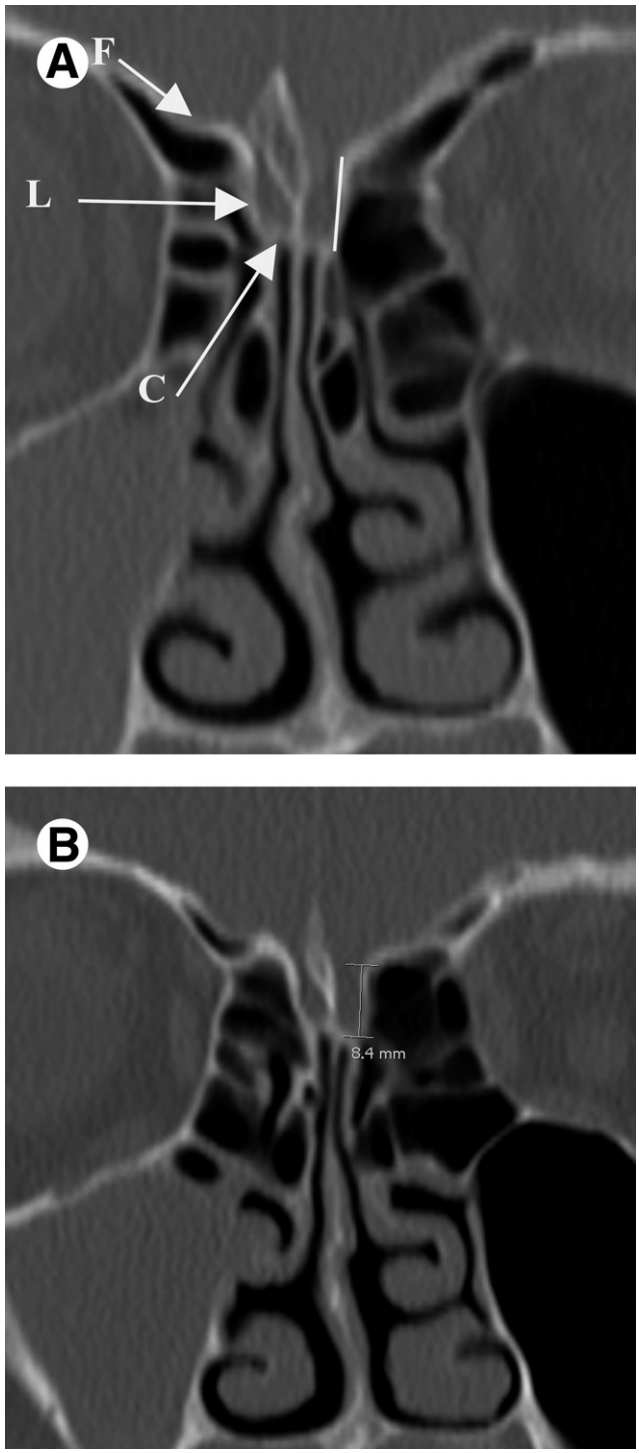

Figure 34 (A and B) Coronal CT demonstrating a deep olfactory fossa and therefore low cribriform plate (C). Both the cribriform plate and the lateral lamella (L) are at risk if frontoethmoidal surgery is being considered. (B) The measurement (8.4 mm) highlights the vertical depth of the olfactory fossa in this case.

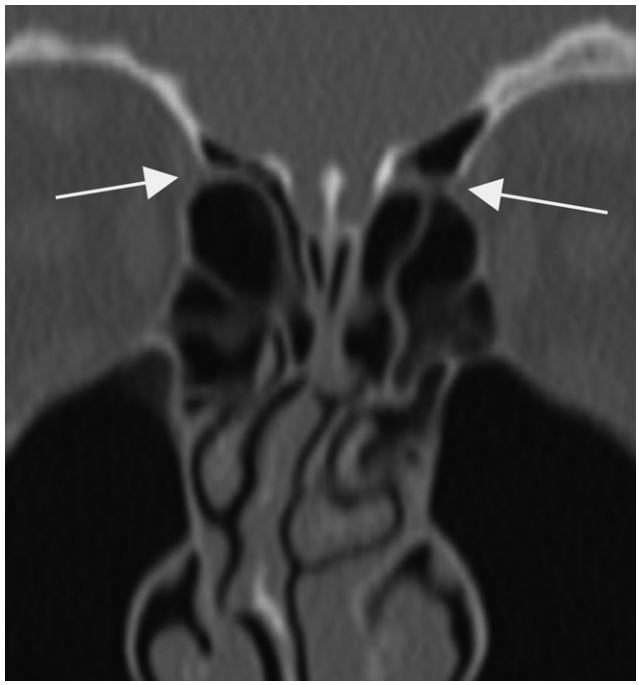

Figure 35 Coronal CT demonstrating the anterior ethmoidal artery canal (white arrow). The artery may hang on a mesentery and is at particular risk of trauma in patients with a large suprabullar recess. When traumatized it may retract and bleed into the orbit.

Conclusion

It is important to have a logical approach to assessing the sinonasal anatomy and understand the anatomical variants that are relevant to the surgeon. The CT study should be reviewed in all three orthogonal planes in order to accurately understand this complex region.

References

1. Earwacker J: Anatomic variants in sinonasal CT. Radiographics 13:381-415, 1993
2. Lee WT, Kuhn FA, Citardi MJ: 3D computed tomographic analysis of frontal recess anatomy in patients without frontal sinusitis. Otolaryngology Head Neck Surg 131(3):164-173, 2004
3. Stammberger H, Kopp W, Dekornfeld TJ, et al: Functional endoscopic sinus surgery? Eur Arch Otorhinolaryngol 63-76, 1990
4. Kasper KA: Nasofrontal connections. A study based on one hundred consecutive dissections. Arch Otolaryngol 23:322-343, 1936
5. Kuhn FA, Javer AR: Primary endoscopic management of the frontal sinus. Oper Tech Otolaryngol Head Neck Surg 7:222-229, 1996
6. Wormald P-J: Endoscopic Sinus Surgery. New York, NY, Thieme, 2005
7. Bruner E, Jacobs JB, Lebowitz RA, et al: Role of the agger asi air cell in chronic frontal sinusitis. Ann Otol Laryngol 105:694-700, 1996
8. Owen RG, Kuhn FA: Supraorbital ethmoid cell. Otolaryngol Head Neck Surg 116:254-261, 1997
9. Joe J, Ho S, Yanagisawa E: Documentation of variations in sinonasal anatomy by intraoperative nasal endoscopy. Laryngoscope 110:229-235, 2000
10. Sarna A, Hayman A, Laine F, et al: Coronal imaging of the ostiomeatal unit: anatomy of 24 variants. J Computer Assisted Tomogr 26(1):153-157, 2002
11. Zeinrich SJ, Mattox DE, Kennedy DW, et al: Concha bullosa: CT evaluation. J Comput Assist Tomogr 12:778-784, 1988

12. Cannon CR: Endoscopic management of concha bullosa. Otolaryngol Head Neck Surg 110:449-454, 1994
13. Stammberger H, Wolf G: Headaches and sinus disease: the endoscopic approach. Ann Otol Rhinol Laryngol Suppl 134:3-23, 1988
14. Bolger WE, Butzin CA, Parsons DS: Paranasal sinus bony anatomic variations and mucosal abnormalities: CT analysis for endoscopic sinus surgery. Laryngoscope 101:56-64, 1991
15. Jog M, McGarry GW: How frequent are accessory sinus ostia? J Laryngol Otol 117:270-272, 2003
16. Maniscalo JE, Habal MB: Microanatomy of the optic canal. J Neurosurg 48:402-406, 1978
17. Bayram M, Sirikci A, Bayazit YA: Important anatomic variations of the sinonasal anatomy in light of endoscopic surgery: a pictorial review. Eur Radiol 11:1991-1997, 2001