

# Hereditary hemorrhagic telangiectasia-related epistaxis: innovations in understanding and management

Nathan B. Sautter, MD and Timothy L. Smith, MD, MPH

**Background:** Epistaxis is the most common manifestation of hereditary hemorrhagic telangiectasia (HHT), affecting approximately 90% of patients at some point during their lifetime. Bleeding is chronic and varies from mild, self-limited episodes to severe, transfusion-dependent or life-threatening epistaxis. Treatment options vary from conservative, nonsurgical management to more aggressive surgical approaches. A number of treatment options have been introduced in recent years. There is little consensus in the literature regarding treatment algorithms. The objective of this investigation was to provide a contemporary review of HHT-related epistaxis, including pathophysiology, disease manifestations, and state-of-the-art treatment modalities.

**Methods:** A systematic review of the literature for HHT-related epistaxis was performed using the search terms “hereditary hemorrhagic telangiectasia” and “epistaxis.” Additional literature search regarding current recommendations for HHT evaluation and recent developments in genetic mechanisms, pathophysiology, and treatment of HHT was also performed.

**Results:** A total of 308 articles were identified and reviewed for appropriateness of inclusion whereas 64 articles

met inclusion criteria. Treatment options range from topical and hormonal therapy to more aggressive surgical modalities. Most treatment descriptions are case series, with few randomized controlled trials. A number of new and novel therapies have been introduced in recent years.

**Conclusion:** HHT is a heterogeneous disease requiring multidisciplinary evaluation and treatment. Therapeutic options for HHT-related epistaxis vary from conservative, nonsurgical measures to more aggressive surgical treatments. A graduated treatment plan is recommended. Patients present with a wide degree in variation of severity of epistaxis, and treatment is best tailored to the individual patient. © 2012 ARS-AAOA, LLC.

**Key Words:** hemorrhagic disorders; hereditary; epistaxis; therapeutics; review; chronic disease

**How to Cite this Article:**

Sautter NB, Smith TL. Hereditary hemorrhagic telangiectasia-related epistaxis: innovations in understanding and management. *Int Forum Allergy Rhinol*, 2012; 2:422-431.

Hereditary hemorrhagic telangiectasia (HHT), also known as Osler-Weber-Rendu disease, is an autosomal dominant disease with an estimated prevalence of 1 in 5000.<sup>1</sup> Nearly all HHT patients are prone to formation of multiple telangiectasias involving all aspects of the mucosa lining the nasal cavity. Consequently, recurrent spon-

aneous epistaxis is the most common presenting symptom of the disease. In a population-based study, 50% of patients developed recurrent epistaxis before the age of 20 years, and 96% of patients suffered from frequent nosebleeds at some point during their lifetime.<sup>2</sup> Incidence, therefore, increases with age, and it is not uncommon for patients to present with increasingly severe epistaxis in the fourth or fifth decade without a prior diagnosis of HHT. Recurrent epistaxis often leads to iron-deficiency anemia as well as chronic crusting and nasal obstruction. Patients with HHT report a significant detriment to quality of life, which increases with the duration and frequency of epistaxis.<sup>3,4</sup> In rare cases, the severity of epistaxis is life-threatening.

HHT-related epistaxis presents a treatment challenge to the otolaryngologist. The recurrent and chronic nature of the disease, as well as the wide variation in severity of bleeding should be considered prior to surgical treatment. Surgical options include potassium-titanyl-phosphate

Oregon Sinus Center, Department of Otolaryngology-Head and Neck Surgery, Oregon Health and Science University, Portland, OR

Correspondence to: Nathan B. Sautter, MD, Department of Otolaryngology-Head and Neck Surgery, Oregon Health and Science University, 3181 SW Sam Jackson Park Road, PV-01, Portland, OR 97239; e-mail: sauttern@ohsu.edu

Potential conflict of interest: T.L.S. is a research consultant for Intersect ENT (Palo Alto, CA), which provided no financial support for this investigation; he is also funded by the National Institute on Deafness and Other Communication Disorders.

Received: 4 January 2012; Revised: 15 March 2012; Accepted: 20 March 2012  
DOI: 10.1002/alr.21046

View this article online at [wileyonlinelibrary.com](http://wileyonlinelibrary.com).

(KTP) laser ablation, coblation therapy, bipolar electro-surgery techniques, septodermoplasty, and Young's procedure (nasal closure). There is a relative paucity of literature, however, addressing surgical treatment of HHT. Expert opinion guides most treatment decisions, and evidence-based treatment guidelines are largely lacking. The objectives of this review are to provide a background of the disease process from an otolaryngic perspective, and to evaluate contemporary treatment options, providing the advantages and disadvantages of each modality based upon the existing literature.

## Diagnosis

Typically, patients are referred to the otolaryngologist for treatment of epistaxis following initial diagnosis. In rare instances, patients presenting with frequent and recurrent epistaxis will arrive without a prior diagnosis. Aside from intranasal telangiectasias, which commonly involve the septum and lateral nasal wall, other common manifestations of HHT include mucocutaneous telangiectasias involving the oral cavity and skin. Arteriovenous malformations (AVMs) involving the lungs, brain, gastrointestinal (GI) tract, and liver are less common, but may be associated with significant morbidity if left untreated. Approximately 15% to 50% of HHT patients harbor pulmonary AVMs, and cerebral vascular malformations are present in approximately 23% of patients.<sup>5-8</sup> In contrast, 80% of HHT patients will exhibit telangiectasias in the gastric and small intestine mucosa, but only 25% to 30% of patients will develop symptomatic GI bleeding at some point in their life.<sup>1,2,9</sup>

In 2000, publication of the Curaçao Criteria established consensus clinical diagnosis based on the presence of several clinical criteria (Table 1).<sup>10</sup> A "definite" diagnosis is made based on the presence of 3 or more criteria, and a "possible or suspected" diagnosis is made if 2 criteria are present. Diagnosis is "unlikely" if 1 or 0 criterion are present.

## Pathophysiology

Endothelial dysfunction is the starting point in the pathogenesis of HHT. Dysfunction of the transforming growth factor (TGF)- $\beta$  signaling pathway in vascular endothelial

cells results in unregulated vessel wall remodeling within the mucosa and viscera. This leads to loss of elastic elements, resulting in markedly dilated and convoluted post-capillary venules, which often connect directly to dilated arterioles.<sup>11</sup> Mutations in the endoglin (ENG, HHT type 1) and activin receptor-like kinase 1 (ACVRL1, HHT type 2) genes are responsible for 90% of cases of HHT.<sup>12</sup> In rare instances, mothers against decapentaplegic homolog 4 (MADH4) gene mutations lead to a combined clinical picture of juvenile polyposis and HHT.<sup>13</sup> Two other HHT loci have been identified, but the specific genes have yet to be identified.<sup>14,15</sup>

Genotype/phenotype correlations have been observed in so-called HHT1 (endoglin) and HHT2 (activin receptor-like kinase 1) patients. Patients with HHT1 experience epistaxis at an earlier age and have a higher frequency of pulmonary AVMs, whereas HHT2 patients are more likely to have hepatic involvement.<sup>16</sup> Telangiectasias become more prominent with time, which mirrors the increase in severity of epistaxis. Due to expense and the wide variations in genetic mutations, routine diagnostic genetic testing is generally not recommended. Expert guidelines do recommend genetic testing of the index patient in order to identify the causative mutation in a family with confirmed HHT. Genetic testing is also indicated in relatives of a patient with known HHT for purposes of prenatal screening, and to establish a diagnosis in relatively asymptomatic relatives of a known HHT patient.<sup>5</sup>

## Evaluation

### History

A careful medical history should be performed for all patients at the time of initial consultation. Frequency, length, and severity of nosebleeds should be documented. Inquiry should be made regarding frequency of ER visits, and need for prior blood transfusions. Documentation of the number of prior transfusions, as well as the time period between infusions aids in quantifying the severity of bleeding. Patients should be asked about the known presence of any pulmonary, intracranial or GI AVMs. Family history is nearly always positive for 1 or more first-degree family members with recurrent epistaxis and/or a diagnosis of HHT. A validated epistaxis severity scale for HHT-related epistaxis is available, and may be useful for following patients' symptoms over time as well as response to treatment.<sup>17</sup> While it is common for nosebleeds to slowly increase in severity with age, a more rapid increase in epistaxis frequency or severity warrants further evaluation, as it may herald the onset of high-output cardiac failure or formation of an intranasal AVM.<sup>18,19</sup>

### Physical exam

A complete examination of the upper aerodigestive tract should be performed during the initial visit. Patients will often present with significant crusting involving the

**TABLE 1.** Curaçao Criteria for clinical diagnosis of hereditary hemorrhagic telangiectasia

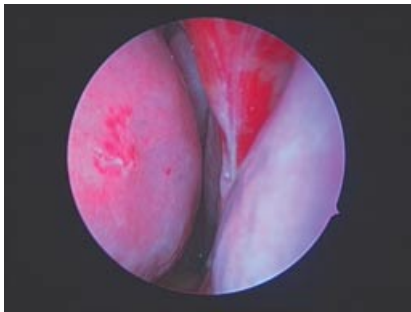
Criteria	Description
Epistaxis	Spontaneous and recurrent
Telangiectasias	Multiple, at characteristic sites: lips, oral cavity, fingers, nose
Visceral lesions	Gastrointestinal telangiectasia, and pulmonary, hepatic, cerebral or spinal arteriovenous malformations
Family history	A first-degree relative with HHT according to these criteria

HHT = hereditary hemorrhagic telangiectasia.

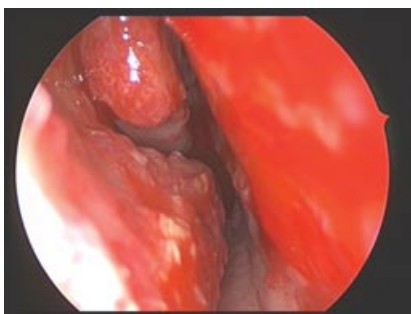anterior nasal septum, and inferior turbinates. Examination in the office should proceed with caution due to the high risk of active bleeding during debridement of crusting and endoscopic examination.

Anterior rhinoscopy allows for visualization of telangiectasias arising from the anterior nasal septum, nasal vestibule, and inferior turbinates. Careful application of topical decongestants and anesthetics may aid in visualization. Soaking a cotton ball with a combination topical local anesthetic and decongestant such as lidocaine/oxymetazoline and placing it in the nose for several minutes allows for vasoconstriction and anesthesia while hydrating crusts and dry blood clots present in the nasal vestibule and anterior nasal septum. Gentle debridement of crusting and blood clots is often necessary to visualize the underlying mucosa, especially in patients with a history of septodermoplasty or scarring from prior epistaxis management. It is not uncommon for patients with multiple prior surgeries to present with septal perforation, which can also be a nidus for large crusts.

Endoscopic examination is best accomplished with a 2.9-mm 30-degree rigid nasal endoscope. This allows for magnified views of the inferior turbinates, septum, and middle turbinates. While they are typically most prominent along the anterior nasal septum, telangiectasias may be found throughout the sinonasal cavity. Appearance may vary from small, punctate lesions (Fig. 1) to large conglomerate telangiectasias (Fig. 2).



**FIGURE 1.** Endoscopic view of nasal cavity demonstrating a single, punctate telangiectasia on the right inferior turbinate. Note the presence of a large septal perforation.



**FIGURE 2.** Endoscopic view of the right nasal cavity demonstrating large conglomerations of telangiectasias involving the inferior turbinate, head of the middle turbinate, and septum.

**TABLE 2.** Preoperative testing in HHT patients

Preoperative tests
Bubble echocardiogram (rule out pulmonary AVMs)
Baseline hemoglobin and hematocrit
Type and cross

AVM = arteriovenous malformation; HHT = hereditary hemorrhagic telangiectasia.

### Laboratory testing and imaging

Laboratory testing prior to any surgical intervention is generally recommended (Table 2).<sup>5</sup> A recent hemoglobin level and hematocrit should be available. Patients who are severely anemic may be typed and crossed for potential blood transfusion. Patients who undergo regular blood transfusions may opt to have transfusion just prior to the procedure in anticipation of blood loss. HHT patients are often iron deficient, requiring regular iron infusions. A “baseline” hemoglobin level is helpful for future reference. This level varies widely among patients, and in our experience averages around 10 to 11 g/dL. Close follow up and communication with the hematologist or primary care physician is important.<sup>11</sup>

Expert recommendations for screening of GI, pulmonary, and cerebral AVMs are based upon the Curaçao Criteria.<sup>10</sup> Current recommendations dictate that patients with possible or confirmed HHT undergo transthoracic contrast echocardiography at the time of diagnosis and once every 5 to 10 years thereafter. Screening for pulmonary AVMs is also recommended for purposes of prenatal testing. Patients over the age of 35 years are recommended to undergo annual hemoglobin and hematocrit monitoring. Endoscopic evaluation of the upper and lower digestive tracts is indicated in patients presenting with anemia disproportionate to the degree of epistaxis. Current recommendations also include screening brain magnetic resonance imaging (MRI) at the time of diagnosis in patients with possible or definite HHT to rule out the presence of cerebrovascular malformations.<sup>5</sup>

### Treatment

A stepwise approach to treatment is recommended (Table 3).<sup>20</sup> Severity of bleeding and tolerance for epistaxis varies widely among HHT patients, and treatment should be tailored based on patient goals and expectations. Physician and patient collaboration in developing a strategy geared toward reducing epistaxis to a tolerable level often leads to best outcomes.

The following sections will evaluate management options for HHT-related epistaxis. Medical therapies include hydrating saline gels, nasal emollients, and topical or systemic estrogen, among others. Surgical options laser photocoagulation, bipolar cautery, and coblation therapy, among others. Though still commonly used, use of silver nitrate

**TABLE 3. Treatment options for HHT-related epistaxis**

Topical therapies	Indications	Advantages	Disadvantages	Level of evidence	References
Tranexamic acid gel	Mild epistaxis	Commonly used blood loss preventative due to its antifibrinolytic effects	Efficacy for epistaxis is not well established	Single case series (Level IV)	Tibbelin et al. <sup>24</sup>
Estrogen cream	Mild epistaxis	No systemic effects as compared to oral administration, ease of application	Long term use results in squamous metaplasia of nasal mucosa; efficacy for epistaxis is not well established	Single randomized placebo controlled trial (Level II)	Vase <sup>28</sup>
Mupirocin ointment	Mild epistaxis	Decreased crusting and bacterial colonization	No direct effect in terms of epistaxis prevention	Single randomized placebo controlled trial (Level II)	Kubba et al. <sup>25</sup>
Bevacizumab (topical application)	Mild to moderate epistaxis	Ease of application, low risk of adverse reaction	Need for daily, ongoing use. Safety profile has not been well studied for topical application; currently not FDA approved for topical intranasal use	Prospective, randomized placebo controlled multi-institutional trial is ongoing, (Level I, pending)	HHT Foundation <sup>38</sup> (James Gossage)
<b>Local therapies</b>					
Bevacizumab (mucosal injection)	Moderate to severe epistaxis	May provide additional benefit when combined with surgical treatment	Septal perforation if injected into cartilaginous septum	Single case series (Level IV)	Karnezis and Davidson <sup>30</sup>
Sclerotherapy	Mild or moderate epistaxis	In-office procedure	Safety profile not well defined	Single case series (Level IV)	Boyer et al. <sup>29</sup>
<b>Surgical cautery</b>					
Bipolar cautery	Mild to moderate epistaxis	Readily available, may be combined with laser photocoagulation	Deeper degree of thermal injury compared to laser photocoagulation	Single case series (Level IV)	Ghaehri et al. <sup>42</sup>
KTP laser	Moderate to severe epistaxis	Useful for smaller, punctate lesions, very precise	Risk of injury to patient, OR personnel, airway fire; bleeding during procedure can limit visualization	Few case series (Level IV)	Karnezis and Davidson <sup>30</sup> , Harvey et al. <sup>44</sup>

(Continued)

TABLE 3. Continued

	Indications	Advantages	Disadvantages	Level of evidence	References
Nd:YAG laser	Moderate to severe epistaxis	Useful for smaller, punctate lesions, very precise	Risk of injury to patient, OR personnel, airway fire; deeper thermal injury can result in septal perforation	Several case series (Level IV)	Kuhnel et al. <sup>45</sup> ; Mahoney and Shapshay <sup>46</sup> ; Shah et al. <sup>47</sup> ; Kluger et al. <sup>49</sup> ; Karapantzos et al. <sup>51</sup>
Coblation	Moderate to severe epistaxis	Ease of use, higher degree of OR safety compared to laser treatments. Useful for larger, conglomerate lesions. May be combined with laser therapy	Not well-studied, deeper degree of thermal injury and less precise than laser treatments	Single report (Level IV)	Sautter <sup>53</sup>
Other surgical therapies					
Septodermoplasty	Severe epistaxis, or moderate epistaxis not responsive to more conservative treatment	Effective for near-cessation of bleeding for up to 2 years	Destructive, loss of native nasal mucosa resulting in increased crusting. Donor site morbidity for skin graft	Several case series (Level IV)	Lesnik et al. <sup>41</sup> ; Harvey et al. <sup>44</sup> ; Ross and Nguyen <sup>56</sup>
Young's procedure	Life-threatening or severely recalcitrant epistaxis	Complete cessation of bleeding in most reports	Loss of nasal function, obligatory mouth breathing	Few case series (Level IV)	Saunders <sup>54</sup> ; Siegel et al. <sup>55</sup> ; Ross and Nguyen <sup>56</sup> ; Gluckman et al. <sup>59</sup> ; Hosni and Innes <sup>60</sup> ; Lund and Howard <sup>61</sup>
Systemic therapies					
Estrogen/anti-estrogen therapy	Mild, moderate, or severe epistaxis	Prevention of osteoporosis	May only be used in female patients	Prospective, randomized, placebo controlled trials (Level I)	Albinana et al. <sup>31</sup> ; Jameson and Cave <sup>32</sup> ; Yaniv et al. <sup>33</sup>

FDA = U.S. Food and Drug Administration; HHT = hereditary hemorrhagic telangiectasia; OR = operating room.

cautery is generally not recommended in most cases because it is often inadequate, imprecise, and understudied.<sup>21</sup>

### Preventive measures

Little evidence is available regarding conservative measures for HHT-related epistaxis, or for conservative management of epistaxis in general.<sup>22</sup> Patients with HHT will often develop their own techniques for maintenance and prevention of nosebleeds and much can be learned from their personal successes. There are numerous nasal sprays, gels, ointments, and emollients available over the counter that are associated with minimal risk from long-term use. There is no evidence available to recommend any 1 humidification/emollient treatment over another.<sup>5</sup> The underlying theme in terms of epistaxis prevention, however, is nasal hydration. Drying and crusting of the nasal mucosa secondary to repeated trauma, bleeding, scarring, and inflammation is a significant issue with HHT patients, and patients should be counseled regarding a regular nasal hygiene regimen aimed at preventing desiccation of the mucous membranes with subsequent buildup of crusting.

Helpful suggestions may include installation of a humidifier in the bedroom, particularly during cold and dry weather when risk of epistaxis is more prominent. Saline gels formulated with hyaluronic acid are more effective and longer lasting than saline nasal sprays in terms of maintenance of nasal hydration.<sup>23</sup> Tranexamic acid nasal gels have been proposed by some authors, and may be available through compounding pharmacies.<sup>24</sup> Topical formulations with antimicrobial activity, such as mupirocin, may be helpful in reducing crusting and bacterial colonization.<sup>25</sup> Some patients prefer petroleum products, although data regarding the risk of long-term use with possible pulmonary sequelae is lacking.<sup>26</sup> Frequent and liberal application of topical agents is key to successful epistaxis prevention.

Some patients may tolerate gentle nasal saline irrigations using a squeeze bottle, piston syringe, or Neti pot. Irrigations help prevent buildup of crusting deeper within the nasal cavity where other topical formulations may be less effective. Many patients do not tolerate saline irrigations, as the act of irrigation may be an instigating factor for epistaxis.

### Medical management

There has been significant recent interest in the medical management of HHT-related epistaxis. Specifically, advances in treatment with bevacizumab (Avastin, Genentech, San Francisco, CA), are promising. Other medical treatments include estrogen and sclerotherapy.<sup>27-30</sup>

Increasing interest has been seen regarding treatment with estrogen, estrogen modifiers, and estrogen antagonists for HHT-related epistaxis. Raloxifene, a selective estradiol receptor modulator (SERM) much like tamoxifen, has been shown to increase expression of endoglin and activin receptor-like kinase 1 (ALK1), thus helping to counter haploinsufficiency at the level of the endothelium.<sup>31</sup>

In a prospective study of 19 postmenopausal women with HHT-related epistaxis treated with raloxifene, Albinana et al.<sup>31</sup> noted a significant decrease in severity and frequency of bleeding as measured by a questionnaire. In 2004, Jameson and Cave<sup>32</sup> reported 2 cases of dramatic improvement in HHT-related epistaxis in postmenopausal women treated with tamoxifen. Subsequently, in a randomized, prospective, placebo-controlled study of 21 men and women with HHT-related epistaxis, tamoxifen treatment was associated with decreased severity and frequency of bleeding as measured by questionnaire and endoscopic examination. Additionally, hemoglobin levels rose during treatment in approximately 20% of patients.<sup>33</sup> It is worth noting that women treated with unopposed estrogen therapy are at increased risk for endometrial cancer, and may be at higher risk for breast cancer and ovarian cancer with long-term estrogen replacement therapy.

In a randomized, placebo-controlled double-blind study evaluating topical estrogen treatment for HHT-related epistaxis, improvement in subjective epistaxis was observed, but no significant changes in hemoglobin levels were seen.<sup>28</sup> In a separate study evaluating argon laser photocoagulation followed by topical estriol application, Sadick et al.<sup>34</sup> noted significant decrease in frequency and intensity of bleeding as reported by patient questionnaire, as compared to argon laser treatment followed by topical dexpanthenol ointment application. Electron microscopy of nasal tissue in patients undergoing topical estriol treatment demonstrated squamous metaplasia of the respiratory epithelium.

Office-based sclerotherapy has been proposed recently as a treatment alternative for HHT-related epistaxis. Boyer, et al.<sup>29</sup> describe a series of 7 patients who were treated in the office setting using intralesional injections of sodium tetradecyl sulfate (STS). The average period of time between treatments was 3.1 months, and patients underwent an average of 5 treatments. There were no complications reported, and all patients noted improvement in epistaxis as reported by questionnaire. Unfortunately, no further descriptions of sclerotherapy for HHT-related epistaxis exist outside of this small case series.

Recently, much interest has surrounded the use of bevacizumab (Avastin), a monoclonal antibody inhibitor of the vascular endothelial growth factor (VEGF)-A receptor, for treatment of HHT-related epistaxis. Rationale for treatment is based on the fact that elevated plasma levels of VEGF are present in patients with HHT.<sup>35</sup> Several authors have noted improvement in anemia and cardiac output following intravenous bevacizumab therapy in HHT. Brinkerhoff et al.<sup>36</sup> present a case report of a 55-year-old woman with HHT with a rise in severity of epistaxis as a result of chemotherapy treatment, progressing to the point of transfusion dependence. She responded favorably to several intravenous (IV) infusions of bevacizumab with temporary cessation of epistaxis altogether. This was followed by regular treatments with topical intranasal bevacizumab. The authors noted that topical treatments resulted in excellent control of epistaxis for at least 8 weeks at a time.

Several recent studies have investigated the safety and efficacy of topical and/or injected intranasal bevacizumab treatment in patients with HHT-related epistaxis. Use of bevacizumab is limited by cost, which is greater than \$700 per vial, and is unlikely to garner reimbursement from medical insurance. Chen et al.<sup>37</sup> treated 52 patients with either submucosal injections or topical spray application of bevacizumab (doses ranging from 25-100 mg per treatment), many cases in conjunction with KTP laser photocoagulation. Patients were sent questionnaires in follow-up ranging from 1.5 to 46 months. Five patients (10%) sustained a septal perforation, but no other significant adverse effects were noted. It was noted that all patients who developed a septal perforation had undergone bevacizumab submucosal injection in the cartilaginous septum. Once this was recognized, no further injections in the cartilaginous septum were performed, and no additional patients developed septal perforation. Further follow-up in 32 patients revealed significant improvement in epistaxis as measured by the ESS.<sup>30</sup>

While it remains a promising treatment, long-term data regarding topical bevacizumab treatment is lacking. Currently, a double-blinded, placebo-controlled multi-institutional trial evaluating topical bevacizumab nasal spray vs topical estrogen spray (North American Study of Epistaxis in HHT, or NOSE study) is underway.<sup>38</sup> Safety and stability of long-term storage of bevacizumab in benzalkonium chloride solution for nasal spray application has been established.<sup>39</sup> Further study is ongoing.

Thalidomide is another antiangiogenic agent that has been used in the treatment of HHT-related epistaxis. Thalidomide is believed to exert its effects by modulating components of the VEGF pathway and acting upon endothelial tip cells of immature vessels. The only description of its use in the literature comes as a small case series as reported by Lebrin et al.<sup>40</sup> Seven patients with severe, recurrent, HHT-related epistaxis were treated with 100 mg daily oral thalidomide. Six of the patients experienced lowered frequency of epistaxis during the course of treatment, and 5 patients experienced an increase in hemoglobin concentration. Four patients with prior regular transfusion requirements did not require any transfusions during the treatment period. It should be noted that use of thalidomide is limited by its well-described teratogenic effects.

### Surgical management techniques

Surgical management for HHT-related epistaxis runs the gamut from nasal packing, which is useful as a temporizing measure prior to more formal endonasal treatments such as telangiectasia ablation, progressing to partial septectomy, septodermoplasty, and nasal closure (Young's procedure). The surgical technique should be tailored to the individual patient and severity of bleeding, and a stepwise approach starting with less aggressive treatments progressing to more invasive techniques is recommended.<sup>20</sup>

One of the most common long-term consequences of surgical therapy is septal perforation.<sup>41</sup> The use of monopolar electrocautery and silver nitrate have been associated

with an increase in the incidence of septal perforation, though any surgical manipulation of the septal mucoperichondrium could result in increased risk of perforation.<sup>21</sup> Regardless of the chosen technique, care should be taken to avoid injury to the underlying perichondrium when treating telangiectasias of the cartilaginous nasal septum, if possible. Some surgeons endorse staggered unilateral treatments to help reduce the risk of perforation; however, bilateral surgery is appropriate as long as care is taken to avoid injury to opposing areas of the cartilaginous septum.<sup>42</sup>

### Bipolar electrocoagulation

Bipolar electrocoagulation of intranasal telangiectasias is a widely available treatment for HHT-related epistaxis. However, only 1 retrospective case series exists in the literature. Ghaheri et al.<sup>42</sup> describe a series of 18 patients undergoing 42 bipolar treatments for HHT-related epistaxis using the Landolt bipolar coagulator (B. Braun Medical Inc., Bethlehem, PA). One-half of the treatments were performed in conjunction with laser photocoagulation. No complications were noted, including synechia formation or septal perforation. The authors conclude that the bipolar is useful both as an adjunct to laser therapy, as well as a stand-alone technique, especially in cases where larger, conglomerate telangiectasias are present.

### Laser photocoagulation

Several forms of laser photocoagulation have been described in the treatment of HHT-related epistaxis, including the argon laser (variable wavelength), the potassium titanium phosphate (KTP) laser (585 nm), and the neodymium-doped yttrium aluminum garnet (Nd:YAG) laser (1064 nm).<sup>34,43-49</sup> Advantages of laser therapy include the potential for precise treatment of telangiectasias in a "rosette" fashion with minimal injury to the adjacent normal mucosa, as well as minimal depth of thermal injury. Use of standard laser precautions including wet towel drapes and moist eye pads to protect the patient's skin and eyes is recommended.<sup>50</sup> Access to laser technology may be limited at some centers due to cost and/or lack of available equipment.

The largest case series for patients undergoing laser treatment of HHT-related epistaxis was described by Harvey et al.<sup>44</sup> One hundred and thirty-one patients underwent 268 KTP laser treatments over a 60-month period. The majority of patients required 3 or fewer procedures. The mean time interval between treatments was 473 days, and the authors note that the benefits of KTP laser treatment are time-limited. Karnezis and Davidson<sup>30</sup> report a series of 12 HHT patients treated concomitantly with the KTP laser and submucosal bevacizumab with significant reduction in postoperative bleeding as measured by the epistaxis severity score. Septal perforation was reported as a complication, but only in patients who underwent injection of bevacizumab into the cartilaginous septum.<sup>30</sup>

Several retrospective case series have been published describing use of the Nd:YAG laser for HHT-related epistaxis. Kuhnel et al.<sup>45</sup> describe a series of 30 patients undergoing treatment with significant decrease in the frequency of bleeding postoperatively. Multiple treatments were performed at individually appointed time periods, but the authors did not specify the average amount of time between treatments. Mahoney and Shapshay<sup>46</sup> describe a retrospective series of 40 patients undergoing Nd:YAG laser treatment. The authors describe 3 different vascular patterns, and found that patients with isolated, punctate lesions or large solitary malformations fared better with laser treatment, whereas patients with diffuse, conglomerate lesions responded better to treatment with septodermoplasty. As compared to the KTP laser, the Nd:YAG laser has a greater depth of penetration resulting in increased scarring and fibrosis.<sup>51</sup>

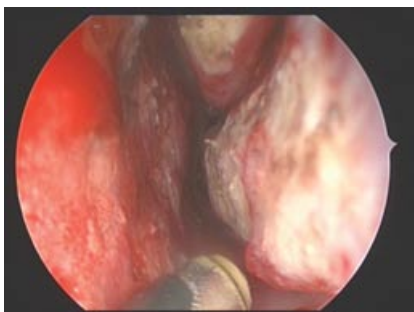Reports of the argon laser for treatment of HHT-related epistaxis are limited. Hitchings et al.<sup>52</sup> describe a series of 15 patients undergoing treatment. The authors did not observe any significant change in bleeding following the procedure.

### Coblation

Recently, the coblation wand was approved by the U.S. Food and Drug Administration (FDA) for use in the nasal cavity (Fig. 3). Coblation technology utilizes low-heat plasma energy to ablate and cauterize telangiectasias. There are currently no published studies evaluating use of the coblator for treatment of HHT-related epistaxis, and only 1 preliminary report is available.<sup>53</sup> In this series, the surgeons reported a higher degree of ease of use with the coblation wand as compared to the KTP laser. The authors also noted other advantages of the coblator over laser treatment, such as an increased level of operating room (OR) safety and a higher degree of availability. Early data suggests improved patient satisfaction with coblation treatment as compared to the laser. Further study is ongoing.

### Septodermoplasty

Septodermoplasty (SDP) was first described by Saunders in 1960.<sup>54</sup> This technique involves removal of the mucosa



**FIGURE 3.** Endoscopic view of the left nasal cavity demonstrating the tip of the coblator wand as the surgeon is preparing to ablate a telangiectasia on the inferior turbinate. Note the areas previously cauterized on the inferior turbinate and head of the middle turbinate.

overlying the anterior one-half of the nasal septum with preservation of the underlying perichondrium, followed by placement of a split-thickness skin graft or buccal mucosal graft.<sup>55</sup> This may also be performed in conjunction with removal of the inferior turbinates with extension of the graft onto the lateral nasal wall, as described by Ross and Nguyen.<sup>56</sup> Few case series exist describing authors' experience with the technique in patients with moderate to severe HHT-related epistaxis. Harvey et al.<sup>44</sup> describe a series of 33 patients undergoing SDP, resulting in greater than 50% reduction in need for subsequent laser treatments over a 60-month time period. Lesnik et al.<sup>41</sup> describe a series of 9 patients undergoing partial septectomy with SDP for severe transfusion-dependent HHT-related epistaxis. Treatment resulted in significant improvement in quality of life (QOL) as well as significant reduction in transfusion requirements. Patients should be counseled that SDP will result in some loss of normal mucociliary function within the anterior nasal cavity, resulting in chronic crusting.<sup>56</sup> This may be obviated by maintenance of a daily nasal hygiene regimen. Also, SDP results are generally not permanent because vessel regrowth into or surrounding the graft with reformation of telangiectasias occurs within 2 years, which may result in the need for revision procedures.<sup>57</sup>

### Nasal closure

Young's procedure, or closure of the anterior nares, was first described for treatment of chronic crusting related to atrophic rhinitis.<sup>58</sup> This procedure was revisited for the treatment of HHT-related epistaxis by Gluckman and Portugal<sup>59</sup> in a case series of 3 patients, and subsequently by Hosni and Innes<sup>60</sup> in 2 patients. Lund and Howard<sup>61</sup> describe a series of 12 patients undergoing nasal closure for severe HHT-related epistaxis. Eleven of 12 patients reported complete cessation of bleeding; the remaining patient underwent unilateral nasal closure and experienced continued epistaxis from the open nostril. The authors note that unilateral closure is an option in patients without septal perforation who present with severe unilateral epistaxis. The technique involves raising skin and mucosal flaps either through an endonasal approach or via an alotomy incision for increased exposure. The flaps are closed in a double-layered fashion, allowing for complete closure of the nares. Elimination of airflow through the nasal cavity reportedly results in complete elimination of epistaxis. However, this technique also results in complete nasal obstruction requiring obligatory mouth-breathing, as well as loss of olfaction. Use of a silastic nasal obturator has been described by some authors as an alternative to permanent nasal closure, thus providing a reversible alternative to complete loss of nasal function.<sup>62</sup> Based on the literature, nasal closure is an effective treatment for severe life-threatening or transfusion-dependent epistaxis in select patients when other treatments such as ablation or septodermoplasty are inadequate or unsuccessful. A recent case report described severe life-threatening epistaxis in a patient despite prior nasal closure.



Management in this case required endovascular therapy and ultimate reopening of the nares for surgical management of the epistaxis (The information is currently being presented at COSM (Combined Otolaryngology Spring Meeting) in San Diego. It is poster #1-154, Author is Jonathon Ting.).


### Endovascular embolization

Endovascular treatment for HHT-related epistaxis has been described; however, only a limited number of small, retrospective studies have been published in the last 20 years. Layton et al.<sup>63</sup> describe a series of 12 patients with HHT-related epistaxis treated with endovascular embolization. As compared to patients with idiopathic nosebleeds, HHT patients required more frequent re-embolization and surgical treatments. Also, 69% of patients with HHT had significant mucosal contributions from the ethmoidal branches of the ophthalmic artery as compared to 9% of patients with idiopathic bleeding. This may be due to the likelihood that the majority of patients with non-HHT epistaxis presenting for embolization therapy are bleeding from branches of the sphenopalatine artery, whereas patients with HHT-related epistaxis tend to present with anterior epistaxis from the region of Kiesselbach's plexus. A separate study by Braak et al.<sup>64</sup> described 12 patients with HHT-related epistaxis who underwent percutaneous embolization treatment. An improvement in the duration between episodes of epistaxis was noted up to 1 year following embolization. A significant drawback to endovascular embolization therapy is the inability to treat the anterior and posterior ethmoid artery branches due to high risk of stroke and blindness. These risks often overshadow the potential advantages of endovascular therapy over more traditional surgical approaches; ie, avoidance of general anesthetic and nasal instrumentation. Therefore, endovascular embolization treatment for HHT-related epistaxis is rarely indicated over more standard surgical approaches.<sup>5</sup>

### Follow-up

Close follow-up is recommended for patients undergoing surgical as well as more conservative treatment measures. Counseling regarding the chronic and progressive nature of the disease is helpful for patients to understand the need for ongoing maintenance therapy designed to prevent nasal dryness and crusting. Patients may also require frequent clinic visits for endoscopic debridement if crusting is more severe. Additional surgical treatments may become necessary when the degree of bleeding is severe enough to interfere with daily activities, or when bleeding is felt to contribute to anemia or need for blood transfusions. Procedures may be required every several months or every few years depending on the severity of disease and the chosen surgical modality.

### Conclusion

Epistaxis is the most common symptom of HHT. A number of therapies are available, ranging from conservative, nonsurgical measures to surgical treatments such as electrosurgery, laser photocoagulation, and septodermoplasty. HHT patients present with varying degrees of severity of epistaxis, and a graduated treatment plan is suggested, beginning with more conservative techniques. Invariably, recurrent bleeding secondary to reformation of telangiectasias occurs at some point following treatment, except in patients undergoing complete nasal closure in whom results appear to be mostly permanent. A multidisciplinary team approach involving pulmonary and hematology specialists is helpful for evaluation and treatment of other manifestations of the disease, such as multiorgan system AVMs and chronic anemia. Treatment is best tailored to the individual patient, and close follow-up and counseling is necessary given the chronic nature of the disease. Additional updates regarding advances in HHT therapy, patient resources, and other HHT-related information are available through the nonprofit HHT Foundation (<http://www.hht.org>). 

### References

- Kjeldsen AD, Vase P, Green A. Hereditary hemorrhagic telangiectasia: a population-based study of prevalence and mortality in Danish patients. *J Intern Med*. 1999;245:31–39.
- Plauchu H, de Chadarevian JP, Bideau A, Robert JM. Age-related clinical profile of hereditary hemorrhagic telangiectasia in an epidemiologically recruited population. *Am J Med Genet*. 1989;32:291–297.
- Ingrand I, Ingrand P, Gilbert-Dussardier B, Defossez G, et al. Altered quality of life in Rendu-Osler-Weber disease related to recurrent epistaxis. *Rhinology*. 2011;49:155–162.
- Loaec ML, Moriniere S, Hitier M, Ferrant O, Plauchu H, Babin E. Psychosocial quality of life in hereditary haemorrhagic telangiectasia patients. *Rhinology*. 2011;49:164–167.
- Faughnan ME, Palda VA, Garcia-Tsao G, et al. International guidelines for the diagnosis and management of hereditary haemorrhagic telangiectasia. *J Med Genet*. 2011;48:73–87.
- Maher CO, Piepgras DG, Brown RD Jr, Friedman JA, Pollock BE. Cerebrovascular manifestations in 321 cases of hereditary hemorrhagic telangiectasia. *Stroke*. 2001;32:877–882.
- Morgan T, McDonald J, Anderson C, Ismail M, Miller F, Mao R, et al. Intracranial hemorrhage in infants and children with hereditary hemorrhagic telangiectasia (Osler-Weber-Rendu syndrome). *Pediatrics*. 2002;109:E12.
- Fulbright RK, Chaloupka JC, Putman CM, Sze GK, Merriam MM, et al. MR of hereditary hemorrhagic telangiectasia: prevalence and spectrum of cerebrovascular malformations. *AJNR Am J Neuroradiol*. 1998;19:477–484.
- Ingrosso M, Sabba C, Pisani A, et al. Evidence of small bowel involvement in hereditary hemorrhagic telangiectasia: a capsule-endoscopic study. *Endoscopy*. 2004;36:1074–1079.
- Shovlin CL, Guttmacher AE, Buscarini E, et al. Diagnostic criteria for hereditary hemorrhagic telangiectasia (Rendu-Osler-Weber syndrome). *Am J Med Genet*. 2000;91:66–67.
- Guttmacher AE, Marchuk DA, White RI. Hereditary hemorrhagic telangiectasia. *N Engl J Med*. 1995;333:918–924.
- Lesca G, Burnichon N, Raux G, et al. Distribution of ENG and ACVRL1 (ALK1) mutations in French HHT patients. *Hum Mutat*. 2006;27:598.
- Gallione CJ, Repetto GM, Legius E, et al. A combined syndrome of juvenile polyposis and hereditary haemorrhagic telangiectasia associated with mutations in MADH4 (SMAD4). *Lancet*. 2004;363:852–859.
- Cole SG, Begbie ME, Wallace GM, Shovlin CL. A new locus for hereditary haemorrhagic telangiectasia (HHT3) maps to chromosome 5. *J Med Genet*. 2005;42:577.
- Bayrak-Toydemir P, McDonald J, Akarsu N, et al. A fourth locus for hereditary hemorrhagic telangiectasia maps to chromosome 7. *Am J Med Genet A*. 2006;140:2155–2162.
- Dupuis-Girod S, Bailly S, Plauchu H. Hereditary hemorrhagic telangiectasia: from molecular biology to patient care. *J Thrombosis Haemostasis*. 2010;8:1447–1456.
- Hoag JB, Terry P, Mitchell S, et al. An epistaxis severity score for hereditary hemorrhagic telangiectasia. *Laryngoscope*. 2010;120:838–843.
- Khalid SK, Pershbacher J, Makan M, Barzilai B, Goodenberger D. Worsening of nose bleeding heralds high cardiac output state in hereditary hemorrhagic telangiectasia. *Am J Med*. 2009;122:779.e1–779.e9.

19. Bhandarkar ND, Sautter NB. A novel approach to treatment of nasal septal arteriovenous malformation. Presented at Combined Otolaryngology Spring Meeting, April 2010, Las Vegas, NV.
20. Lund VJ, Howard DJ. A treatment algorithm for the management of epistaxis in hereditary hemorrhagic telangiectasia. *Am J Rhinol*. 1999;13:319–322.
21. McCaffrey TV, Kern EB, Lake CF. Management of epistaxis in hereditary hemorrhagic telangiectasia. Review of 80 cases. *Arch Otolaryngol*. 1977;103:627–630.
22. Kara N, Spinou C, Gardiner Q. Topical management of anterior epistaxis: a national survey. *J Laryngol Otol*. 2009;123:91–95.
23. Messick D, Hurtuk A. Effectiveness of a nasal saline gel in the treatment of recurrent anterior epistaxis in anticoagulated patients. *Ear Nose Throat J*. 2011;90:E4–E6.
24. Tibbelin A, Aust R, Högleron S, et al. Effect of local tranexamic acid gel in the treatment of epistaxis. *ORL J Otorhinolaryngol Relat Spec*. 1995;57:207–209.
25. Kubba H, MacAndie C, Botma M, et al. A prospective, single-blind, randomized controlled trial of antiseptic cream for recurrent epistaxis in childhood. *Clin Otolaryngol*. 2001;26:465–468.
26. Loughran S, Spinou E, Clement WA, et al. A prospective, single-blind, randomized controlled trial of petroleum jelly/Vaseline for recurrent paediatric epistaxis. *Clin Otolaryngol*. 2004;29:266–269.
27. Bergler W, Sadick H, Gotte K, Riedel F, Hormann K. Topical estrogens combined with argon plasma coagulation in the management of epistaxis in hereditary hemorrhagic telangiectasia. *Ann Otol Rhinol Laryngol*. 2002;111:222–228.
28. Vase P. Estrogen treatment of hereditary hemorrhagic telangiectasia. A double-blind controlled clinical trial. *Acta Med Scand*. 1981;209:393–396.
29. Boyer H, Fernandes P, Duran O, et al. Office-based sclerotherapy for epistaxis due to hereditary hemorrhagic telangiectasia: a pilot study. *Int Forum Allergy Rhinol*. 2011;1:319–323.
30. Karnezis TT, Davidson TM. Efficacy of intranasal bevacizumab (Avastin) treatment in patients with hereditary hemorrhagic telangiectasia-associated epistaxis. *Laryngoscope*. 2010;121:636–638.
31. Albinana V, Bernabeu-Herrero ME, Zarrabeitia R, et al. Estrogen therapy for hereditary hemorrhagic telangiectasia (HHT): effects of raloxifene on endoglin and ALK1 expression in endothelial cells. *Thromb Haemost*. 2010;103:525–534.
32. Jameson JJ, Cave DR. Hormonal and antihormonal therapy for epistaxis in hereditary hemorrhagic telangiectasia. *Laryngoscope*. 2004;114:705–709.
33. Yaniv E, Preis M, Hadar T, et al. Antiestrogen therapy for hereditary hemorrhagic telangiectasia: a double-blind placebo-controlled clinical trial. *Laryngoscope*. 2009;119:284–288.
34. Sadick H, Ramin N, Oulmi J, et al. Plasma surgery and topical estriol: effects on the nasal mucosa and long-term results in patients with Osler's disease. *Otolaryngol Head Neck Surg*. 2003;128:233–238.
35. Sadick H, Riedel F, Naim R, et al. Patients with hereditary hemorrhagic telangiectasia have increased plasma levels of vascular endothelial growth factor and transforming growth factor-beta 1 as well as high ALK1 tissue expression. *Haematologica*. 2005;90:818–828.
36. Brinkerhoff BT, Choong NW, Treisman JS, Poetker DM. Intravenous and topical intranasal bevacizumab (Avastin) in hereditary hemorrhagic telangiectasia. *Am J Otolaryngol*. (in press).
37. Chen S, Karnezis T, Davidson TM. Safety of intranasal bevacizumab (Avastin) treatment in patients with hereditary hemorrhagic telangiectasia-associated epistaxis. *Laryngoscope*. 2010;121:644–646.
38. HHT Foundation. North American Study of Epistaxis (NOSE) in HHT. Patient recruitment begins. <http://www.hht.org/docs/NOSE.Study.2011.pdf>. Accessed December 18, 2011.
39. Kaja S, Hilgenberg JD, Everett E, et al. Effects of dilution and prolonged storage with preservative in a polyethylene container on bevacizumab (Avastin) for topical delivery as a nasal spray in anti-hereditary hemorrhagic telangiectasia and related therapies. *Hum Antibodies*. 2011;20:95–101.
40. Lebrin F, Srun S, Raymond K, et al. Thalidomide stimulates vessel maturation and reduces epistaxis in individuals with hereditary hemorrhagic telangiectasia. *Nat Med*. 2010;16:420–428.
41. Lesnik GT, Ross DA, Henderson KJ, et al. Septectomy and septal dermoplasty for the treatment of severe transfusion-dependent epistaxis in patients with hereditary hemorrhagic telangiectasia and septal perforation. *Am J Rhinol*. 2007;21:312–315.
42. Ghaheri BA, Fong KJ, Hwang PH. The utility of bipolar electrocautery in hereditary hemorrhagic telangiectasia. *Otolaryngol Head Neck Surg*. 2006;134:1006–1009.
43. Bergler W, Riedel F, Baker-Schreyer A, Juncker C, Hormann K. Argon plasma coagulation for the treatment of hereditary hemorrhagic telangiectasia. *Laryngoscope*. 1999;109:15–20.
44. Harvey RJ, Kanagalingam J, Lund VJ. The impact of septodermoplasty and potassium-titanyl-phosphate (KTP) laser therapy in the treatment of hereditary hemorrhagic telangiectasia-related epistaxis. *Am J Rhinol*. 2008;22:182–187.
45. Kuhnle TS, Wagner BH, Schurr CP, Strutz J. Clinical strategy in hereditary hemorrhagic telangiectasia. *Am J Rhinol*. 2005;19:508–513.
46. Mahoney EJ, Shapshay SM. Nd-YAG laser photocoagulation for epistaxis associated with hereditary hemorrhagic telangiectasia. *Laryngoscope*. 2005;115:373–375.
47. Shah RK, Dhingra JK, Shapshay SM. Hereditary hemorrhagic telangiectasia: a review of 76 cases. *Laryngoscope*. 2002;112:767–773.
48. Lennox PA, Harries M, Lund VJ, Howard DJ. A retrospective study of the role of the argon laser in the management of epistaxis secondary to hereditary haemorrhagic telangiectasia. *J Laryngol Otol*. 1997;111:34–37.
49. Kluger PB, Shapshay SM, Hybels RL, et al. Neodymium-YAG laser intranasal photocoagulation hereditary hemorrhagic telangiectasia: an update report. *Laryngoscope*. 1987;97:1397–1401.
50. Sliney DH. Laser safety. *Lasers Surg Med*. 1995;16:215–225.
51. Karantzios I, Tsimpiris N, Goulis DG, et al. Management of epistaxis in hereditary hemorrhagic telangiectasia by Nd:YAG laser and quality of life assessment using the HR-QoL questionnaire. *Eur Arch Otorhinolaryngol*. 2005;262:830–833.
52. Hitchings AE, Lennox PA, Lund VJ, Howard DJ. The effect of treatment for epistaxis secondary to hereditary hemorrhagic telangiectasia. *Am J Rhinol*. 2005;19:75–78.
53. Sautter NB. Coblation treatment of HHT-related epistaxis: a preliminary report (poster presentation). American Rhinologic Society Annual Meeting, September 2011, San Francisco, CA.
54. Saunders WH. Permanent control of nosebleeds in patients with hereditary hemorrhagic telangiectasia. *Ann Intern Med*. 1960;53:147–152.
55. Siegel MD, Keane WM, Atkins JF, Rosen MR. Control of epistaxis in patients with hereditary hemorrhagic telangiectasia. *Otolaryngol Head Neck Surg*. 1991;105:675–679.
56. Ross DA, Nguyen DB. Inferior turbinectomy in conjunction with septodermoplasty for patients with hereditary hemorrhagic telangiectasia. *Laryngoscope*. 2004;114:779–781.
57. McCabe WP, Kelly AP Jr. Management of epistaxis in Osler-Weber-Rendu disease: recurrence of telangiectases within a nasal skin graft. *Plast Reconstr Surg*. 1972;50:114–118.
58. Young A. Closure of the nostrils in atrophic rhinitis. *J Laryngol Otol*. 1967;81:515–524.
59. Gluckman JL, Portugal LG. Modified Young's procedure for refractory epistaxis due to hereditary hemorrhagic telangiectasia. *Laryngoscope*. 1994;104:1174–1177.
60. Hosni AA, Innes AJ. Hereditary hemorrhagic telangiectasia: Young's procedure. *J Laryngol Otol*. 1994;108:754–757.
61. Lund VJ, Howard DJ. Closure of the nasal cavities in the treatment of refractory hereditary haemorrhagic telangiectasia. *J Laryngol Otol*. 1997;111:30–33.
62. Woolford TJ, Loke D, Bateman ND. The use of a nasal obturator in hereditary hemorrhagic telangiectasia: an alternative to Young's procedure. *J Laryngol Otol*. 2002;116:455–456.
63. Layton KF, Kallmes DF, Gray LA, Cloft HJ. Endovascular treatment of epistaxis in patients with hereditary hemorrhagic telangiectasia. *AJNR Am J Neuroradiol*. 2007;28:885–888.
64. Braak SJ, de Witt CA, Disch FJM, Overtoon TTC, Westermann JJ. Percutaneous embolization on hereditary hemorrhagic telangiectasia patients with severe epistaxis. *Rhinology*. 2009;47:166–171.